

## Effect of Propolis on Immunotoxicity Induced by Phenol Subchronic Use in Adult Albino Rats

SAID SAID ELSHAMA, HOSAM-ELDIN HUSSEIN OSMAN, and AYMAN EL-MEGHAWRY EL-KENAWY\*

*For author affiliations, see end of text.*

Received July 12, 2014; Revised April 4, 2015; Accepted May 25, 2015

This paper is available online at <http://ijpt.iums.ac.ir>

### ABSTRACT

Phenol is naturally found in some foods and animal wastes. It is also used as a disinfectant, insecticide and in some pharmaceutical products. Immunotoxicity is considered to be one of the harmful health effects of phenol. Propolis is a mixture of beeswax and resins; it has an antimicrobial, anti-inflammatory, antioxidant and immunomodulatory effect. This study investigates effect of propolis on immunotoxicity induced by phenol subchronic use in rats by assessment of the serum immunoglobulins, total and differential blood cells count, immune organs weight and histopathological changes of thymus, spleen and lymph nodes. Eighty adult albino rats were divided into four groups; each group consisted of twenty rats. The control group received water, the second group received phenol only, third group received propolis and the fourth group received propolis with phenol for 90 days via gastric gavage. Phenol Subchronic use led to immunotoxicity manifestations such as a decrease in the serum immunoglobulins and blood cells count, disturbance in the differential white blood cells count, decrease in the rats body, thymus and spleen weight, and histopathological changes in thymus, spleen and lymph nodes that were improved by propolis administration. Concurrent use of propolis with phenol ameliorates phenol-induced immunotoxicity.

**Keywords:** *Phenol, Immunotoxicity, Propolis, Immunomodulatory*

Phenol is a colorless or white solid aromatic organic hydrocarbon compound (monohydroxy derivative of benzene). It is known as a carboxylic acid which is a moderate soluble in water and commercially sold as a liquid. Phenol is naturally found in some foods, human and animal wastes; it is produced endogenously in the gut from aromatic amino acids metabolism [1]. It is also produced from other natural sources such as the coal tar and petroleum to synthesize resins and plastics. Phenol is considered a serious environmental and occupational hazard because of its common use as a disinfectant, insecticide and in some pharmaceutical products such as antiseptic lotions, ointments, ear and nose drops. It is also used as a flavouring substance in the food [2].

Phenol intoxication affects on human and animal leading to many harmful health effects such as nephrotoxicity, hematotoxicity, immunotoxicity,

cytotoxicity and neurotoxicity. This might be due to the phenoxyl-type radical production from phenol that has the ability to impair the epithelial cell membrane integrity [3]. Until now, the available data about the mechanism of phenol-induced immunotoxicity is not enough despite of some studies demonstrated that phenol immunotoxicity may be attributed to the benzene metabolites (a parent chemical of phenol). So, there is a necessity desire for understanding the effect of phenol chronic use on the immune system as an occupational and public health hazard [4].

Propolis is a mixture of beeswax and resins which is collected from the plant different sources (flowers and leaf buds) by honeybees. Chemical composition of propolis depends on the type of plant that is accessible to honeybees and the specificity of local flora at the site of collection. It has more than 300 of identified

constituents such as the plant resins, essential oils, pollen, balm, wax, minerals (zinc, copper, manganese, iron, potassium, calcium, sodium and selenium), vitamins (B<sub>1</sub>, B<sub>2</sub>, B<sub>6</sub>, A, C and E), proteins (amides, amines and amino acids) and the large number of unknown components [5]. Propolis has many beneficial biological influences such as antimicrobial, anti-inflammatory, hepatoprotective, anticancer and antioxidant effect. Therefore, it has been widely used as a popular medicine in the different regions in the world since the ancient times till now [6].

In the recent years, new information was obtained concerning the mechanism of propolis and its effects on the immune system by using the *vitro* and *vivo* assays. It is considered as an immunomodulatory agent because its administration in the animals over a short term led to the best immunological assays results. Some studies demonstrated the modulatory effect of propolis on the murine peritoneal macrophages that increased their microbicidal activity while other studies showed its inhibitory effect on the lymphoproliferation and its stimulant effect on the lytic activity of killer cells against tumor cells and on the antibody production [7].

Therefore, the current study aims to evaluate the propolis effect on immunotoxicity induced by phenol subchronic use in rats by assessment of the serum immunoglobulins level, some hematological indices (total and differential white blood cells, red blood cells and platelets count) and histopathological changes of spleen, thymus gland and lymph nodes.

## MATERIALS AND METHODS

Eighty healthy adult albino rats weighing 150-250 g were obtained from the animal house of King Abdul Aziz University-Jeddah. Rats were exposed to 12-h day and night cycles. They were fed on water and the standard rat pellets during the experimental period. They were divided into four groups; each group comprising of twenty rats. The first control group received distilled water (0.5ml) only while the second group received 180 mg/kg/day of phenol (30% of oral LD<sub>50</sub>), dissolved in distilled water [8]. The third group received 90 mg/kg/day of propolis, dissolved in distilled water while the fourth group received 180 mg/kg/day of phenol and 90 mg/kg/day of propolis, dissolved in distilled water. The daily administration of distilled water, phenol and propolis were done by gastric gavage for 90 days. Phenol (C<sub>6</sub>H<sub>5</sub>OH) was available in the carbolic acid solution with molecular weight 94.11 (Sigma-Aldrich Chemie GmbH, Steinheim, Germany). Oral LD<sub>50</sub> of phenol in rats was determined as 600 mg/kg based on the pilot study on the same species of the used rats in this experiment. Propolis was available in 400 mg capsule form that was manufactured by Sigma Pharmaceuticals Industries for International Business Establishment Co. (IBE Pharma, Nasr City, Cairo, Egypt). The propolis dose in this study was used

according to the previous study of Sartori et al. [9] that represents about 1% of oral LD<sub>50</sub> of propolis in the rats according to Arvouet-Grand et al. [10] and about 1% of oral LD<sub>50</sub> of flavonoids in the rats that are considered the primary constituent of propolis according to Burdock [11]

### *Hematological studies*

On the last day of the experiment, the rats were anaesthetized by diethyl ether. The blood samples were collected from the orbital sinus using the heparinized capillary tubes and collected into EDTA tubes for the red blood cells, white blood cells (total & differential) and platelets count that were performed by quantitative, automated, differential cell counter for diagnostic use (The Beckman Coulter MAXM, Miami, USA) [12].

### *Measurement of Quantitative serum immunoglobulins (Ig)*

The blood samples were left at room temperature for 15-30 minutes to form a clot. The samples were centrifuged at 2000 rpm at 4°C for 10 minutes to remove the clot and to separate the serum sample that was stored at -20°C for the quantitative serum immunoglobulins assay. These samples were used for the evaluation of antibody involved in immunodeficiency via the total assessment of IgG, IgA, and IgM levels together by using the rocket electrophoresis method as a quantitative electroimmunoassay [13]. The rocket electrophoresis depends on the electrophoresis of protein (antigen) in an antibody-containing gel (agarose) that is exposed to an electrical current. The differences of proteins electrical charge lead to the migration of protein components at different rates toward anode or cathode. Carbamylation of the amino acid groups of immunoglobulins (Ig) were carried out before the electrophoresis by placing the test sample for immunoglobulins in the excess of potassium cyanate at 37°C under high pH (8-9) for 30 minutes to increase the charge of the immunoglobulin molecule while there was a slight decrease in the antibody affinity. It should also be noted that the antibodies in the gel remain constant during the electrophoresis in contrast to the carbamylated immunoglobulins that move to the anode. During the application of the electric field, the antigen moves into the gel and forms antigen antibody complexes which aggregate to form visible precipitates at the sidelines of the pathway in which the antigen travels. The sequential utilization of antigen during the formation of the sidelines causes a precipitation zone that has the rocket appearance [14-15].

### *Histopathological studies*

After 24 hours, following the last administration of phenol and propolis, the rats were weighed and sacrificed by cervical dislocation after being excessively anaesthetized. Chest and abdominal incisions were carried out; thymus gland, spleen and lymph nodes were

excised for the weight measurement and the histological studies. The tissue specimens were collected from the four groups. They were then fixed in 10% neutral buffered formalin. The fixed specimens were trimmed, washed and dehydrated in the ascending grades of alcohol, cleared in xylene, embedded in paraffin, sectioned at 4-6  $\mu\text{m}$  thickness and stained by haematoxylen and eosin for an examination by the light microscope [16].

### Statistical analysis

Statistical analysis was performed using SPSS version 17. The data was expressed as mean  $\pm$  SD and the analysis was performed using one-way ANOVA, post-hoc multiple comparisons test (TUKEY) to investigate the difference between the parameters among the different groups where the  $P$  value of 0.05 was considered statistically significant.

### Ethical considerations

The most appropriate animal species were chosen for this research. Promotion of high standard care and animal well-being were exercised at all times. An appropriate sample size was calculated for using the fewest number of animals to obtain the valid results statistically. Painful procedures were performed under anesthesia to avoid any distress and pain. Our standards of animal care and administration were consistent with the requirements and standards of international laws and regulations.

## RESULTS

### *The body, thymus and spleen weight changes in the different groups of rats*

Table 1 represents mean  $\pm$  SD values of the rats' body, thymus and spleen weight. Mean  $\pm$  SD values of the body weight in the control group which received distilled water, the second group which received phenol only, the third group which received propolis only and the fourth group that received phenol and propolis were 184.45 $\pm$ 3.927; 161.5 $\pm$ 3.635; 184.1 $\pm$ 4.025 and 172.2 $\pm$ 5.917 respectively. The value of  $F$  indicated that the difference between the groups was 120.554 with the statistical significance at  $p < 0.001$ . Mean  $\pm$  SD values of thymus weight in the control group, second group, third and the fourth group were 670.8 $\pm$ 6.872; 614.9 $\pm$ 9.64; 670.45 $\pm$ 6.871 and 657.8 $\pm$ 5.406 respectively. The value of  $F$  indicated that the difference between the groups was 257.946 with the statistical significance at  $p < 0.001$ . Mean  $\pm$  SD values of spleen weight in the control group, second group, third and the fourth group were 2.44 $\pm$ 0.351; 1.258 $\pm$ 0.1507; 2.456 $\pm$ 0.374 and 1.710 $\pm$ 0.119 respectively. The value of  $F$  indicated that the difference between the groups was 91.898 with the statistical significance at  $p < 0.001$ .

### *The serum immunoglobulins level assay*

Table 2 represents mean  $\pm$  SD values of the rats' total serum immunoglobulins level. Mean  $\pm$  SD values

of the total serum immunoglobulins level in the control group which received distilled water, the second group which received phenol only, the third group which received propolis only, the fourth group that received phenol and propolis were 1469.93 $\pm$ 84.23755; 1032.004 $\pm$ 19.69059; 1778.311 $\pm$ 85.58604 and 1589.619 $\pm$ 64.60446 respectively. The value of  $F$  indicated that the difference between the groups was 423.099 with the statistical significance at  $p < 0.001$ .

### Hematological findings

#### *Total blood cells count*

Table 3 represents mean  $\pm$  SD values of the total blood cells count in the rats. Mean  $\pm$  SD values of total white blood cells count in the control group which received distilled water, the second group which received phenol only, the third group which received propolis only, the fourth group that received phenol and propolis were 6.678 $\pm$ 0.6644; 2.934 $\pm$ 0.1172; 12.153 $\pm$ 0.6023 and 8.593 $\pm$ 1.4499, respectively. The value of  $F$  indicated that the difference between the groups was 404.875 with the statistical significance at  $p < 0.001$ . Mean  $\pm$  SD values of red blood cells count in the control, second, third and the fourth groups were 4.636 $\pm$ 0.03880; 3.082 $\pm$ 0.2148; 7.928 $\pm$ 0.4978 and 4.816 $\pm$ 0.3953, respectively. The value of  $F$  indicated that the difference between the groups was 548.723 with the statistical significance at  $p < 0.001$ . Mean  $\pm$  SD values of platelets count in the control, second, third and the fourth groups were 348.06 $\pm$ 17.982; 67.8 $\pm$ 25.7878; 442.8 $\pm$ 11.8836 and 272.2 $\pm$ 45.2567, respectively. The value of  $F$  indicated that the difference between the groups was 639.414 with the statistical significance at  $p < 0.001$ .

#### *The differential white blood cells count*

Table 4 represents mean  $\pm$  SD values of the differential white blood cells count in the rats. Mean  $\pm$  SD values of neutrophils count in the control group which received distilled water, the second group which received phenol only, the third group which received propolis only, the fourth group that received phenol and propolis were 59.9 $\pm$ 5.6228; 28.54 $\pm$ 6.2308; 52.5 $\pm$ 7.1279 and 66.86 $\pm$ 5.4928, respectively. The value of  $F$  indicated that the difference between the groups was 146.849 with the statistical significance at  $p < 0.001$ . Mean  $\pm$  SD values of lymphocytes count in the control group, second, third and the fourth groups are 32.78 $\pm$ 5.1582; 53.12 $\pm$ 5.0693; 41.022 $\pm$ 7.1366 and 28.14 $\pm$ 4.6101, respectively. The value of  $F$  indicated that the difference between the groups was 77.086 with the statistical significant at  $p < 0.001$ . Mean  $\pm$  SD values of monocytes count in the control, second, third and the fourth groups are 5.04 $\pm$ 0.8744; 7.66 $\pm$ 2.4679; 5.41 $\pm$ 1.7919 and 3.54 $\pm$ 0.5092, respectively. The value of  $F$  indicated that the difference between the groups was 22.458 with the statistical significance at  $p < 0.001$ . Mean  $\pm$  SD values of eosinophils count in the control, second, third and the fourth groups were 1.64 $\pm$ 0.7611; 4.432 $\pm$ 1.9131; 0.82 $\pm$ 0.3860 and 1.16 $\pm$ 0.6377,

**Table 1.** Comparison between Mean  $\pm$  SD of the body, thymus and spleen weight in the different groups rats

Parameter	Groups				F
	First	Second	Third	Fourth	
<b>Body (g)</b>	184.45 $\pm$ 3.927	161.5 $\pm$ 3.635*	184.1 $\pm$ 4.025	172.2 $\pm$ 5.917**	120.554
<b>Thymus (mg)</b>	670.8 $\pm$ 6.872	614.9 $\pm$ 9.64*	670.45 $\pm$ 6.871	657.8 $\pm$ 5.406**	257.946
<b>Spleen (g)</b>	2.44 $\pm$ 0.351	1.258 $\pm$ 0.1507*	2.456 $\pm$ 0.374	1.710 $\pm$ 0.119**	91.898

Number per group: 20; SD: standard deviation; First group (control) received distilled water; Second group received 180 mg/kg/day of phenol; Third group received 90 mg/kg/day of propolis; Fourth group received 180 mg/kg/day of phenol and 90 mg/kg/day of propolis; \* $P < 0.001$  (significant difference in comparison with the first group); \*\* $P < 0.001$  (significant difference in comparison with the second group)

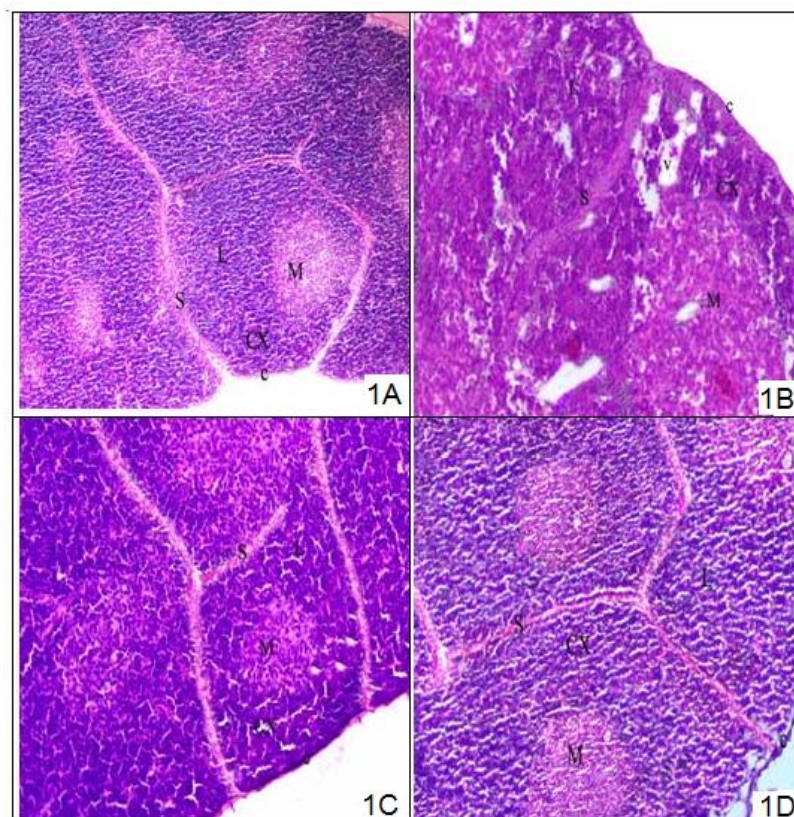
respectively. The value of F indicated that the difference between the groups was 45.276 with the statistical significance at  $p < 0.001$ . Mean  $\pm$  SD values of basophils count in the control, second, third and the fourth groups are 0.64 $\pm$ 0.3761; 1.09 $\pm$ 0.5092; 0.248 $\pm$ 0.0617 and 0.5 $\pm$ 0.4401, respectively. The value of F indicated that the difference between the groups was 16.672 with the statistical significance at  $p < 0.001$ .

### Histopathological findings

#### A- Histopathological findings of thymus gland

The examination of thymus gland tissues in the rats of the first control group showed normal histological

structure of thymus gland (Fig 1A). But the thymus gland tissues in the rats of the second group which received phenol only, showed necrosis, hemorrhage, lymphocytic depletion and fragmented nuclei with vacuolated cytoplasm in the cortex and medulla (Fig 1B). The transverse section of thymus gland in the rats of the third group which received propolis, displayed approximately the same structure of the control group (Fig 1C). The thymus gland tissues of the fourth group rats that received phenol and propolis showed marked improvement of thymus gland injury and histological structures appearance in comparison with the second group that received phenol only (Fig 1D).



**Fig 1.** (A) A photomicrograph of section in the control rat thymus gland shows normal appearance of capsule (c) and septa (S) with incomplete lobules (L), dark peripheral cortex (CX) and light central medulla (M). (B) A photomicrograph of section in the second group rat thymus shows degeneration in the cortex and medulla, lymphocytes infiltration (L), vacuolated cytoplasm (v) in the peripheral cortex (CX) and medulla (M), irregular and thickening of the capsule (c) and septa (S). (C) A photomicrograph of section in the third group rat thymus gland shows normal capsule (c) and septa (S) with normal lobes and incomplete lobules (L), dark peripheral cortex (CX) and light central medulla (M). (D) A photomicrograph of section in the fourth group rat thymus gland shows nearly normal appearance of capsule (c), septa (S), incomplete lobules (L), peripheral cortex (CX) and central medulla (M) (H&E  $\times$ 80).

**Table 2.** Comparison between Mean  $\pm$  SD of the total serum immunoglobulins level in the different groups rats

Parameter	Groups				F
	First	Second	Third	Fourth	
	M $\pm$ SD	M $\pm$ SD	M $\pm$ SD	M $\pm$ SD	
Serum Ig (ng/mL)	1469.93 $\pm$ 84.23755	1032.004 $\pm$ 19.69059*	1778.311 $\pm$ 85.58604	1589.619 $\pm$ 64.60446**	423.099

Number per group: 20; SD: standard deviation; Serum immunoglobulin: Ig; First group (control) received distilled water; Second group received 180 mg/kg/day of phenol; Third group received 90 mg/kg/day of propolis; Fourth group received 180 mg/kg/day of phenol and 90 mg/kg/day of propolis; \* $P < 0.001$  (significant difference in comparison with the first group); \*\* $P < 0.001$  (significant difference in comparison with the second group).

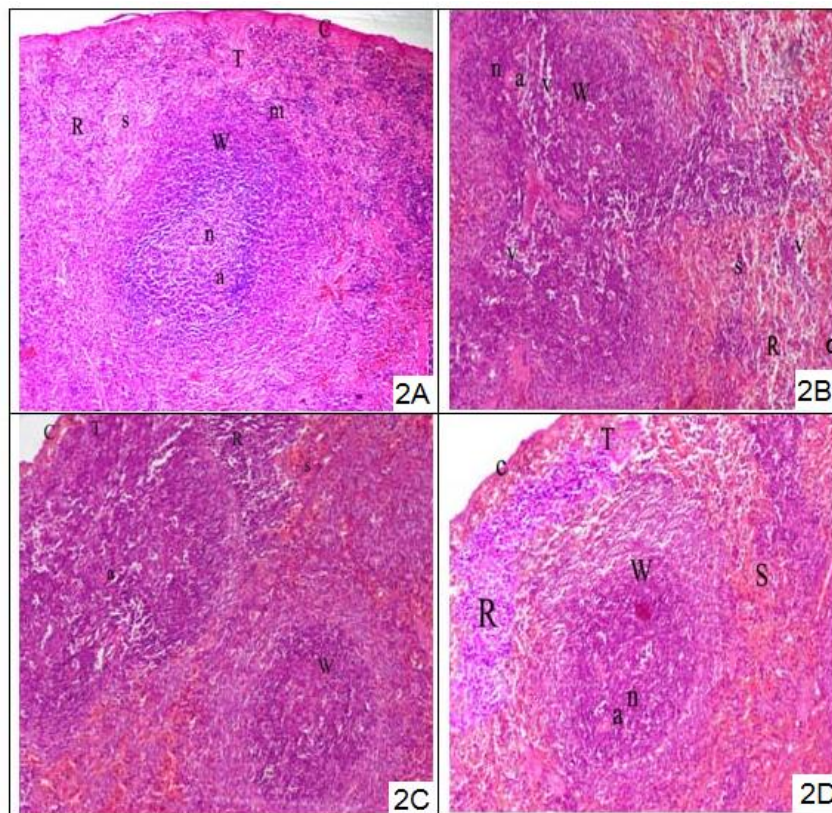
### B- Histopathological findings of spleen

The examination of spleen tissues in the rats of the first control group showed normal histological structure (Fig 2A). The spleen tissue in the rats of the second group showed splenic blood sinuses congestion, fragmented nuclei and vacuolated cytoplasm within the red and white pulps, hemorrhage, lymphocytic necrosis and depletion (Fig 2B). On the other hand, the transverse section of the spleen tissues in the rats of the third group showed normal spleen configuration similar to the first control group (Fig 2C). The spleen tissues in the rats of the fourth group which received phenol and propolis showed marked improvement of spleen lesions

and normal appearance of splenic histological structures in comparison with the second group that received phenol only (Fig 2D).

### C- Histopathological findings of lymph nodes

The examination of lymph nodes sections in the rats of the first control group revealed entirely normal histological features, as illustrated in Fig 3A, while the lymph nodes sections of the second group showed the distortion of lymph nodes architecture, dilatation and congestion of blood vessels, neutrophils and lymphocytes infiltration, macrophages proliferation with vacuolated cytoplasm within the medulla,



**Fig 2.** (A) A photomicrograph of section in the control rat spleen shows normal capsule (C), trabeculae (T), red pulp (R) and white pulp (W), central artery (a) of white pulp is surrounded by lymphoid nodule (n) and the marginal zone (m), the splenic cord is separated by the splenic blood sinuses (s) in the red pulp. (B) A photomicrograph of section in the second group rat spleen shows capsule (C), congestion of the red pulp (R) and splenic blood sinuses (s), congested thick wall of the central artery (a) in the white pulp (W), lymphoid nodule (n) with vacuolated cytoplasm (v) within the white and red pulps. (C) A photomicrograph of section in the third group rat spleen shows normal appearance of capsule (c), red pulp (R) and white pulp (W), normal appearance of central artery (a) in the white pulp that is surrounded by lymphoid nodule (n) and the marginal zone (m), the splenic cord of the red pulp is separated by splenic blood sinuses (s). (D) A photomicrograph of section in the fourth group rat spleen shows nearly normal appearance of capsule (c), trabeculae (T), red pulp (R), white pulp (W), central artery (a), lymphoid nodule (n), marginal zone (m) and the splenic blood sinuses (s) in the red pulp. (H&E  $\times 80$ )

**Table 3.** Comparison between Mean  $\pm$  SD of the total blood cells count in the different groups rats

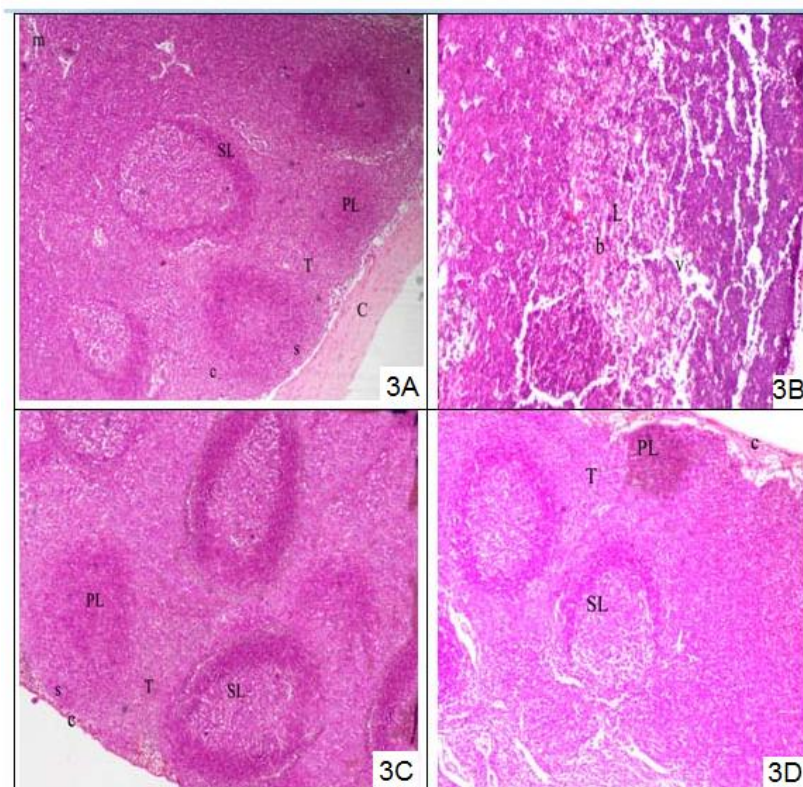
Parameter	Groups				F
	First	Second	Third	Fourth	
	M $\pm$ SD	M $\pm$ SD	M $\pm$ SD	M $\pm$ SD	
WBCs	6.678 $\pm$ 0.6644	2.934 $\pm$ 0.1172*	12.153 $\pm$ 0.6023	8.593 $\pm$ 1.4499**	404.875
RBCs	4.636 $\pm$ .03880	3.082 $\pm$ 0.2148*	7.928 $\pm$ 0.4978	4.816 $\pm$ 0.3953**	548.723
PLAT	348.06 $\pm$ 17.982	67.8 $\pm$ 25.7878*	442.8 $\pm$ 11.8836	272.2 $\pm$ 45.2567**	639.414

Number per group: 20; SD: standard deviation; WBCs: White blood cells; RBCs: Red blood cells; PLAT: Platelet; First group (control) received distilled water; Second group received 180 mg/kg/day of phenol; Third group received 90 mg/ kg/day of propolis; Fourth group received 180 mg/kg/day of phenol and 90 mg/kg/day of propolis; \* $P < 0.001$  (significant difference in comparison with the first group); \*\* $P < 0.001$  (significant difference in comparison with the second group)

lymphoid depletion, focal hemorrhage and the absence of the germinate centers in the cortex (Fig 3B). The lymph nodes tissues of the third group showed normal lymph nodes configuration similar to the control group (Fig 3C). The lymph nodes sections of the fourth group showed marked improvement of lymph nodes lesions and normal histological structures appearance in comparison with the second group that received phenol only (Fig 3D).

### DISCUSSION

Phenol is considered to be one of the most commonly household poisoning because it is used widely as a disinfectant and insecticide [17]. It is also considered a xenobiotic environmental threat to the living organisms. The risk of phenol intoxication on the occupational and public health is increased in the recent years because it is accumulated in the body to cause the harmful influences on the different body systems [18]. Therefore, this study attempts to investigate the



**Fig 3.** (A) A photomicrograph of section in the control rat lymph nodes shows normal capsule (C), trabeculae (T), subcapsular (s), cortical (c) and medullary (m) lymph sinuses, primary lymphoid nodule (PL) and the secondary lymphoid nodule (SL) in the outer cortex. (B) A photomicrograph of section in the second group rat lymph nodes shows degeneration and absence of germinate centers in the cortex, blood vessels congestion (b), lymphocytes infiltration (L) with vacuolated cytoplasm (v) within the cortex and medulla. (C) A photomicrograph of section in the third group rat lymph nodes shows normal appearance of capsule (c), subcapsular (s) and trabeculae (T), normal primary lymphoid nodule (PL) and the secondary lymphoid nodule (SL) with normal cortical lymph (c). (D) A photomicrograph of section in the fourth group rat lymph nodes shows nearly normal appearance of lymphoid cells, capsule (c) and trabeculae (T), normal primary lymphoid nodule (PL) and the secondary nodule (SL) in the outer cortex. (H&E  $\times 80$ )

**Table 4.** Comparison between Mean  $\pm$  SD of the differential white blood cells count in the different groups rats

Parameter	Groups				F
	First	Second	Third	Fourth	
	M $\pm$ SD	M $\pm$ SD	M $\pm$ SD	M $\pm$ SD	
Neutrophils	59.9 $\pm$ 5.6228	28.54 $\pm$ 6.2308*	52.5 $\pm$ 7.1279	66.86 $\pm$ 5.4928**	146.849
Lymphocytes	32.78 $\pm$ 5.1582	53.12 $\pm$ 5.0693*	41.022 $\pm$ 7.1366	28.14 $\pm$ 4.6101**	77.086
Monocytes	5.04 $\pm$ 0.8744	7.66 $\pm$ 2.4679*	5.41 $\pm$ 1.7919	3.54 $\pm$ 0.5092**	22.458
Eosinophils	1.64 $\pm$ 0.7611	4.432 $\pm$ 1.9131*	0.82 $\pm$ 0.3860	1.16 $\pm$ 0.6377**	45.276
Basophils	0.64 $\pm$ 0.3761	1.09 $\pm$ 0.5092*	0.248 $\pm$ 0.0617	0.5 $\pm$ 0.4401**	16.672

Number per group: 20; SD: standard deviation; First group (control) received distilled water; Second group received 180 mg/kg/day of phenol; Third group received 90 mg/ kg/day of propolis; Fourth group received 180 mg/kg/day of phenol and 90 mg/kg/day of propolis; \* $P < 0.001$  (significant difference in comparison with the first group); \*\* $P < 0.001$  (significant difference in comparison with the second group)

immunotoxicity of phenol subchronic use and evaluate the immunomodulatory effect of propolis on the amelioration of this toxicity by assessment of the total immunoglobulins level, some hematological indices and histopathological changes of immune organs.

The current study showed that there is a significant decrease in the rats' body, thymus and spleen weight of the second group which received phenol only in comparison with the control group in agreement with Monfared et al. [8] who indicated that phenol intoxication affects the cellularity of immune organs leading to the atrophy that causes a decrease in the weight. On the other hand, White et al. [19] indicated that phenol toxicity has not any effect on the weight of spleen and thymus gland. There is a significant gain in the rats' body, thymus and spleen weight of the fourth group that received propolis with phenol because the antimicrobial activity of propolis leads to a better intestinal health. The digestion and absorption is improved, consistent with Denli et al. results [20]. On contrary, our results are not in agreement with Koya-Miyata et al. [21] who reported that propolis does not lead to the weight gain although it is considered to be one of the nutritional supplements.

Our results showed a statistically-significant decrease in the total serum immunoglobulins level and the blood cells count (platelets, white and red cells) in the second group which received phenol only in comparison with the control group. In contrast with our results, Hsieh et al. [22] indicated that phenol intoxication has not any significant effect on the total white blood cells and platelets count but they also referred that the red blood cells count and the total serum immunoglobulins level were decreased at the same time, consistent with the current study while White et al. [19] indicated that phenol toxicity has not any significant effect on the total blood cells count and the serum immunoglobulins level. Santa et al. [23] explained that the erythrocytes count reduction is based on the ability of phenol to destruct RBCs due to the interfering with the oxidative phosphorylation, thus the storage of the cell energy in the adenosine triphosphate molecules is prevented leading to the disturbance in the osmotic equilibrium across the cell membranes causing

a hemolysis in agreement with opinion of Michałowicz et al. [24]. In the contrast context, Zaki et al. [25] reported that the red blood cells count showed a significant elevation with phenol intoxication.

The present study demonstrated that there is a statistical significant increase in all differential white blood cells count (Lymphocytes, monocytes, eosinophils and basophils) in the second group which received phenol only in comparison with the control group except the neutrophils which decreased significantly. On contrary, Iwata et al. [26] and Yao and Hou [27] reported that the phenol intoxication causes a decrease in the lymphocytes count as a result of the modulation in the gene expression of mRNA formation leading to an apoptosis, with an inhibition of thymocytes and lymphocytes proliferation in contrast with our results. According to Hammam et al. [28], the hematological changes in the phenol intoxication may be due to reactive oxygen species formation that affect on the substrates and lead to the deoxyribose degradation. Furthermore, the opinion of Baj et al. [1] is in agreement with our results for the increase of monocytes and eosinophils count but they also referred to a decrease in the lymphocytes count in contrast with our results.

The current study showed many histopathological changes in the different immune organs in the second group that received phenol only in comparison with the control group. The thymus gland showed necrosis, hemorrhage and lymphocytic depletion while the spleen showed the blood sinuses congestion, hemorrhage, lymphocytic necrosis and the depletion within the red and white pulps. The lymph nodes displayed the distortion in the architecture, neutrophils and lymphocytes infiltration with focal hemorrhage, macrophages proliferation and lymphoid depletion.

Our results are in consistent with Monfared et al. [11] who indicated that the phenol intoxication leads to toxic histopathological changes in the immune organs such as thymus gland, spleen and lymph nodes because it is considered to be the main primary metabolite of benzene. Phenol is hydroxylated in the liver producing the catechol that is converted into  $\alpha$  benzoquinone which is the responsible for toxic metabolite of the

phenol intoxication mechanism. In the other context, Maleki et al. [29] confirmed that the toxicity of metabolites which are formed during the breakdown of phenol is lower than the toxicity of phenol itself in accordance with Shadnia and Wright [30]. It should also be noted that the free radicals generation and hydrophobicity of phenol may be responsible for the phenol intoxication in accordance with Abd Gami et al. [31]. On contrary, Ryan et al. [32] referred that the phenol intoxication does not cause any alteration in the histological structure of the immune organs.

Immunotoxicity is documented by Kaminski et al. [33] as a disturbance in the normal homeostasis in form of suppression or stimulation of the immune system which consists of particular organs, cells and molecules each playing a critical role in keeping healthy system. Mokarizadeh et al. [34] and Bahadar et al. [35] suggested that the interaction of any chemical agent with the components of the immune system may result in the structural and functional changes in the immune system such as the decrease in the serum immunoglobulins, the reduction in the peripheral blood leukocytes, and the decrease of the thymus and spleen weight in agreement with Veraldi et al. [36]. According to the opinion of Descotes et al. [37], phenol is considered an immunosuppressive agent, because it leads to the alteration in the histological structures of the immune organs such as spleen, thymus and lymph nodes with the reduction in the weight beside the decrease in the serum immunoglobulins level and the total blood cells count especially the peripheral blood leukocytes with a disturbance in its differential count in consistent with our results.

The concurrent use of propolis with phenol in the fourth group revealed marked amelioration in all histopathological changes of thymus gland, spleen and lymph nodes beside the serum immunoglobulins level and the total blood cells count that are increased significantly in comparison with the second group that received phenol only. There is also a statistically-significant decrease in all differential white blood cells count (Lymphocytes, monocytes, eosinophils and basophils) in the fourth group after propolis administration with phenol except neutrophils that increased significantly. These changes in the differential white blood cells count were within the normal limit. According to Sforcin [7], propolis has an immunomodulatory action counteracting the histopathological manifestations of phenol immunotoxicity in the immune organs such as thymus gland, spleen and lymph nodes. It also ameliorates the other changes in the total serum immunoglobulins level and the blood cells count because propolis is considered an antioxidant that can stimulate the antioxidants enzymes such as catalase, peroxidase and superoxide dismutase to reduce and prevent the oxidative damage of phenol [38] This means the antioxidant activity of propolis depends on the flavonoids which are capable of scavenging the free radicals and prevent the lipid

peroxidation. Sforcin et al. [39] stated that the flavonoids have anti-inflammatory activity, strengthening the tissue and regenerative effect which all together improve the immune organs injury.

## CONCLUSION

The subchronic use of phenol may lead to immunotoxicity that is manifested by hematological and serum immunoglobulins abnormalities associated with histopathological changes in the immune organs of the rats such as thymus gland, spleen and lymph nodes. Propolis as an immunomodulatory agent may ameliorate phenol-induced immunotoxicity.

## RECOMMENDATION

The propolis should be used as a protective agent to modulate phenol-induced immunotoxicity based on its antioxidant properties. We suggest further studies using the different doses of propolis for different periods to complete this work. Further research in humans is recommended in order to verify our results.

## REFERENCES

1. Baj Z, Majewska E, Zeman K. The effect of chronic exposure to formaldehyde, phenol and organic chlorohydrocarbons on peripheral blood cells and the immune system in humans. *J Invest Allergol Clin Immunol* 1994; 4: 186-91.
2. Finkelstein Y, Rezvani M, Garcia-Bournissen F, Nurmohamed L. Inactive pharmaceutical ingredients: implications for pregnancy. *Can J Clin Pharmacol* 2007; 14:17-28.
3. Tootian Z, Louei Monfared A, Fazelipour S, Sheibani MT, Rouholla F, Sasani F, Molaemi E. Biochemical and structural changes of the kidney in mice exposed to phenol. *Turk J Med Sci* 2012; 42:695-703.
4. Avogbe PL, Ayi-Fanou L, Cachon B, Chabi N, Debende A, Dewaele D, Aissi F, Cazier F, Sanni A. Hematological changes among Beninese motor-bike taxi drivers exposed to benzene by urban air pollution. *Afr J Environ Sci Technol* 2011; 5:464-72.
5. Banskota AH, Tezuka Y, Kadota S. Recent progress in pharmacological research of propolis. *Phytother Res* 2001; 15: 561-71.
6. Bankova V. Recent trends and important developments in propolis research. *Evid Based Complement Alternat Med* 2005; 2: 29-32.
7. Sforcin JM. Propolis and the immune system: a review. *J Ethnopharmacol* 2007; 113:1-14.
8. Monfared AL, Jaafari A, Sheibani MT. Histological and histometrical evidences for phenol immunotoxicity in mice. *Comp Clin Pathol* 2014; 23:529-34.
9. Sartori DRS, Kawakami CL, Orsatti CL, Sforcin JM. Propolis effect on streptozotocin- induced diabetic rats. *J Venom Anim Toxins incl Trop Dis* 2009; 15:93-102.
10. Arvouet - Grand A, Lejeune B, Bastide P, Pouraat A, Legret P. Propolis extract. Part 6. Subacute toxicity and cutaneous primary irritation index. *J Pharmacie Belgique* 1993; 48:165-70.

11. Burdock GA. Review of the biological properties and toxicity of bee propolis. *Food Chem Toxicol* 1998; 36:347-63.
12. Jones AR, Twedl D, Swaim W, Gottfried E. Diurnal change of blood count analytes in normal subjects. *Am J Clin Path* 1996; 106:723-27.
13. Loh RK, Vale S, McLean-Tooke A. Quantitative serum immunoglobulin tests. *Aust Fam Physician* 2013; 42:195-8.
14. Janice TB. Serum albumin and globulin. Clinical methods, the history, physical, laboratory examinations, 3<sup>rd</sup> ed., Boston: Bulterworths, 1990.
15. Walker JM. Rocket immunoelectrophoresis. *Methods Mol Biol* 1984; 1:317-23.
16. Bancroft JD, Gamble M Theory and Practice Histological Techniques, 5<sup>th</sup> ed., Churchill Livingstone. New York, Edinburgh and London, 2002; pp 173-75.
17. Meena MC, Band R, Sharma G. Phenol and Its Toxicity: A Case Report. *Iran J Toxicol* 2015; 8:1222-4.
18. Wasi S, Tabrez S, Ahmad M. Toxicological effect of major environmental pollutants: An overview. *Environ Monit Assess* 2013; 185:2585-93.
19. White KL, Guo TL, Smith MJ. Report to the National Toxicology Program: Immunotoxicity of phenol in Female B6C3F1 mice. *Virginia Commonwealth University, USA*. 2012.
20. Denli M, Cankaya S, Silici S, Okan F, Uluocak AN. Effect of Dietary Addition of Turkish propolis on the Growth Performance, Carcass Characteristics and Serum Variables of Quail (*Coturnixcoturnix japonica*). *Asian-Aust J Anim Sci* 2005; 18:848-54.
21. Koya-Miyata S, Arai N, Mizote A, Taniguchi Y, Ushio S, Iwaki K, Fukuda S. Propolis prevents diet-induced hyperlipidemia and mitigates weight gain in diet-induced obesity in mice. *Biol Pharm Bull* 2009; 32:2022-8.
22. Hsieh GC, Sharma RP, Parker RD, Coulombe RA. Immunological and neurobiochemical alterations induced by repeated oral exposure of phenol in mice. *Eur J Pharmacol* 1992; 228:107-114.
23. Santa N, Bhagyabati S, Jeetenkumar T, Motu T, Lokeshwar Kh, Kulachandra Singh M. Phenol-induced Haemolytic Anaemia. *JACM* 2003; 4: 174-5.
24. Michałowicz J, Duda W. Phenols-Sources and Toxicity. *Polish J of Environ Stud* 2007; 16:347-62.
25. Zaki M, Fawzi O M, Shalaby SI. Phenol Toxicity Affecting Hematological Changes in Cat Fish (*Clarius lazera*). *Life Sci J* 2011; 8:244-8.
26. Iwata M, Eshima Y, Kagechika H, Miyaura H. The endocrine disruptorsnonylphenol and octylphenol exert direct effects on T cells to suppress Th1 development and enhance Th2 development. *Immunol Lett* 2004; 94:135-9.
27. Yao G, Hou Y. Nonylphenol induces thymocyte apoptosis through Fas/FasL pathway by mimicking estrogen in vivo. *Environ Toxicol Pharmacol* 2004; 17:19-27.
28. Hammam AM, Zaki MS, Refaat AY, Fawzi O. Toxicity, Mutagenicity and carcinogenicity of phenols and phenolic compounds on human and living organisms [A Review]. *Adv Environ Biol* 2015; 9:38-48.
29. Maleki A, Mahvi AH, Mesdaghinia A, Naddafi K. Degradation and toxicity reduction of phenol by ultrasound waves. *Bull Chem Soc Ethiop* 2007; 21:33-8.
30. Shadnia H, Wright JS. Understanding the toxicity of phenols: using quantitative structure-activity relationship and enthalpy changes to discriminate between possible mechanisms. *Chem Res Toxicol* 2008; 21:1197-204.
31. Abd Gami A, Shukor MY, Abdul Khalil K, Dahalan FA, Khalid A, Ahmad SA. Phenol and Phenolic Compounds Toxicity. *J Environ Microbiol Toxicol* 2014; 2:11-23.
32. Ryan BM, Selby RR, Gingell JM, Waechter JR, Butala JH, Dimond SS, Dunn BJ, House R, Morrissey R. Two-generation reproduction study and immunotoxicity screen in rats dosed with phenol via the drinking water. *Int J Toxicol* 2001; 20:121-42.
33. Kaminski NE, Faubert K, Holsapple MP. Toxic responses of the immune system. Casarett & Doull's Toxicology, *The Basic Science of Poisons* 2008; 12: 485-555.
34. Mokarizadeh A, Faryabi M, Rezvanfar MA, Abdollahi MA. Comprehensive review of pesticides and the immune dysregulation: mechanisms, evidence and consequences. *Toxicol Mech Methods* 2015; 1-21.
35. Bahadar H, Abdollahi M, Maqbool F, Baeri M, Niaz K. Mechanistic overview of immune modulatory effects of environmental toxicants. *Inflamm Allergy Drug Targets* 2014; 13: 382-6.
36. Veraldi A, Costantini AS, Bolejack V, Miligi L, Vineis P, Van Loveren H. Immunotoxic effects of chemicals: A matrix for occupational and environmental epidemiological studies. *Am J Ind Med* 2006; 49:1046-55.
37. Descotes J, Choquet-Kastylevsky G, Van Ganse E, Vial T. Responses of the Immune System to Injury. *Toxicol Pathol* 2000; 28:479-81.
38. Daleprane JB, Abdalla DS. Emerging Roles of Propolis: Antioxidant, Cardioprotective, and Antiangiogenic Actions. *Evid Based Complement Alternat Med J* 2013; 1:1-8.
39. Sforzin JM, Orsi RO, Bankova V. Effect of propolis, some isolated compounds and its source plant on antibody production. *J Ethnopharmacol* 2005; 98:301-5.

#### CURRENT AUTHOR ADDRESSES

- Said Said Elshama, Department of Forensic Medicine and Clinical Toxicology, College of Medicine, Taif University, Suez Canal University, Taif, Kingdom of Saudi Arabia.
- Hosam-Eldin Hussein Osman, Department of Anatomy, College of Medicine, Taif University , Al-Azhar University, Taif, Kingdom of Saudi Arabia.
- Ayman El-Meghawry El-Kenawy, Department of Pathology, College of Medicine, Taif University, Department of Molecular Biology, GEBRI, University of Sadat City, Taif, Kingdom of Saudi Arabia.  
E-mail: [elkenawyay@yahoo.com](mailto:elkenawyay@yahoo.com) (Corresponding author)