

Toxicological and Pathological Evaluation of Prolonged Bromuconazole Fungicide Exposure in Male Rats

AHMED H. OSMAN, Ph.D.¹; SAID S. EL-SHAMA, M.D.²; AFAF S. OSMAN, M.D.³ and
AYMAN K. ABD EL-HAMEED, Ph.D.²

The Departments of Pathology¹, Forensic & Clinical Toxicology² and Pharmacology³, College of Medicine, Taif University, KSA, and Faculty of Medicine, Cairo and Suez Canal Universities

Abstract

Background: Fungicides are widely used for keeping of consumed vegetables and fruits fresh for long period in supermarkets. The tested fungicide Bromuconazole in our study is a triazole fungicide used primarily in enclosed commercial greenhouses to control diseases as (black spot) in bananas, cereals, grapes, rice and vegetables.

Objective: The present study aimed to evaluate toxicological effects and histopathological changes following chronic administration of Bromuconazole fungicide in male rats.

Materials and Methods: The animals were divided into three groups; each consisting of 10 animals. The first group was served as control. The second and third groups were given Bromuconazole at daily doses of 36.5 and 18.25mg/kg b.wt. for 3 months, respectively. The selected dosages for the second and third groups were corresponding to 1/10 and 1/20 LD₅₀, respectively.

Results: A significant increase in the hepatic and renal tissue malondialdehyde (MDA), serum activities of alanine aminotransferase (ALT), aspartate aminotransferase (AST), γ -glutamyl transpeptidase (GGT), acid phosphatase and serum levels of alpha fetoprotein (AFP), urea and creatinine. Decreases in serum alkaline phosphatase activity, reduced glutathione (GSH) content in the liver and kidney and the hepatic antioxidant enzymes [superoxide dismutase (SOD), catalase (CAT), glutathione peroxidase (GSH-px) and glutathione reductase (GSH-R)] activities were also recorded. Moreover, exposure to Bromuconazole caused severe necrobiotic and proliferative changes in most of the investigated organs.

Conclusion: Our results indicated that Bromuconazole treatment induced a dose-dependent histopathological alterations and cellular proliferation in the investigated organs with subsequent significant disturbances in their antioxidant defense mechanisms and serum biochemical parameters. Moreover, the serum level of alpha fetoprotein was increased suggesting a carcinogenic potential of this fungicide on prolonged exposure.

Key Words: Bromuconazole – Fungicide – Liver – Kidney – Renal pelvis – Urinary bladder – Testis – Thyroid – Pancreases – Antioxidants – Lipid peroxidation – Superoxide dismutase – Glutathione – Catalase – Rats.

Introduction

FUNGICIDES are pesticides that specifically inhibit or kill fungi underlying diseases important to man. Understanding mechanisms of fungicide action and toxicity is important because humans encounter these pesticides through a wide variety of applications [1].

Nowadays, fungicides are widely used for keeping of consumed vegetables and fruits fresh for long period in supermarkets. Moreover, Triazole fungicides are economically important agricultural chemicals as they are widely used on crops such as wheat, barley, and orchard fruits [2,3].

Bromuconazole belongs to the group of triazole fungicides. It is used as a broad-spectrum fungicide, with preventative and curative action, for control of diseases caused by ascomycetes, basidiomycetes, and deuteromycetes [4].

Most of triazole fungicides had been recorded as hepatotoxic agents in experimental animals because trans-Bromuconazole is a chiral chemical representative of a class of triazole derivatives known to inhibit specific fungal cytochrome P-450 (CYP) reactions [5-9].

Moreover, some of them have been associated with increased incidences of liver adenomas in mice [10]; hydronephrosis and urothelial hyperplasia in renal pelvis and urinary bladder in rats, mice

Correspondence to: Dr. Ahmed Hassan Osman, The Department of Pathology, Medical College, Taif University (KSA),
[Email: ahosman2007@hotmail.com](mailto:ahosman2007@hotmail.com)

and dogs [11] and hyperplasia of thyroid follicular epithelial cells in rats [12].

Bromuconazole is rapidly absorbed and almost completely eliminated in the rat. It is widely distributed in tissues, mainly in liver and kidney, fat, ovaries and uterus tissue. Bromuconazole is extensively metabolised, through oxidation and ring-opening of the tetrahydrofurane moiety, followed by a glucuronide-conjugation or by the formation of a sulphate ester and hydroxylation of the phenyl ring [13]. Its recorded toxicity data include the acute oral LD₅₀ in rats (365mg/kg) with only few records showing that Bromuconazole exposure of rats produced several lesions in all parenchymatous organs including hepatoma with a subsequent increase in liver weight [14].

These toxicity evaluations have been performed only within regulatory submission requirements [14]. Comprehensive data assessing its biological effects has been very limited. Moreover, data addressing its possible adverse effects on prolonged exposure are almost completely lacking. Therefore, the present study aimed to evaluate toxicological effects and histopathological changes following chronic administration of Bromuconazole fungicide in male rats.

Material and Methods

Chemicals:

Bromuconazole, 1-[[4-bromo-2-(2, 4 - dichlorophenyl) tetrahydro-2-furanyl] methyl]-1H-1, 2, 4-triazole. CAS-RN/116255-48-2. Developmental code LS 860263 is the most commonly used triazole fungicide in Arab Gulf. The commercial formulation contains 100g/L Bromuconazole [13] was used in this study. Thiobarbituric acid, reduced and oxidized glutathione, glutathione reductase, epinephrine, MDA-bis (dimethylacetate), glacial metaphosphoric acid, and 5, 5-dithiobis (2-nitrobenzoic acid) were purchased from Sigma Chemical Co. (St. Louis, MO).

Animals:

Thirty adult male rats (190-200g) were used in this study. All animals were kept for 2 weeks under our laboratory conditions and fed with pelleted food and tap water.

Experimental design:

The animals were divided into three groups; each consisting of 10 animals. The first group was kept without any treatment and served as control. The second and third groups were given Bromu-

conazole at daily doses of 36.5 and 18.25mg/kg b.wt. for 3 months, respectively. The selected dosages for the second and third groups were corresponding to 1/10 and 1/20 LD₅₀, respectively [13].

After the end of exposure period, all of experimental and control groups were sacrificed 24 hrs after the last dose by decapitation under ether anesthesia and blood samples were collected for measurement of serum biochemical parameters. Liver and kidney tissue samples were immediately frozen and stored at -40°C for malondialdehyde (MDA), reduced glutathione (GSH) and antioxidant enzyme assays. Tissue specimens from different organs were collected and kept in 10% formalin for the histopathological examination.

Measurement of hepatic and renal lipid peroxidation level:

The lipid peroxidation level in liver and kidney was estimated by the thiobarbituric acid "TBA" method was measured spectrophotometrically at absorbance of 532nm. A standard curve was prepared using known concentrations of MDA and data were expressed as nanomol MDA per mg protein [15].

Measurement of hepatic tissue glutathione level:

Reduced glutathione (GSH) was measured in liver according to Chanarin [16].

Measurement of Serum biochemical parameters:

Blood samples were centrifuged at 4000 rpm for 15min to separate serum. The serum level of alpha fetoprotein was determined using the micro-particle enzyme immunoassay (MEIA) according to Abelev [17]. Commercially accessible test kits were used for estimation of serum activities of ALT, AST [18], γ -glutamyl transpeptidase (GGT) [19], alkaline phosphatase [20], acid phosphatase [21], blood urea [22] and creatinine [23].

Histopathological examination:

Tissue specimens from liver, kidney, urinary bladder; testis, thyroid gland and pancreas of treated and control rats were fixed in 10% neutral buffered formalin solution. The fixed specimens were trimmed, washed and dehydrated in ascending grades of alcohol, cleaned in xylene, embedded in paraffin then sectioned (4-6 micron) and stained with hematoxyline and eosin according to Bancroft & Cook [24].

Statistics:

Statistical comparison of the results of control and treated groups was carried out by one-way analysis of variance (ANOVA) test according to Snedecor and Cochran [25].

Results**Effects on hepatic and renal tissue lipid peroxidation and Glutathione levels:**

The effects of Bromuconazole on malondialdehyde (MDA) and reduced glutathione (GSH) level in liver and kidneys of rats are presented in Table (1) which revealed significant increase of MDA level and reduced GSH concentration in exposed animals.

Table (1): Changes in the levels of MDA and GSH in livers and kidneys of rats treated orally with Bromuconazole fungicide for 3 months.

Groups	Parameters	Liver		Kidney	
		MDA (nmol/mg protein)	GSH (nmol/mg protein)	MDA (nmol/mg protein)	GSH (nmol/mg protein)
Control		0.85±0.06	121.63±10.16	0.82±0.07	32.73±3.26
(18.25 mg/kg b.wt.)		1.77±0.08 ^a	96.66±9.68 ^a	1.35±0.08 ^a	22.75±2.28 ^a
(36.50 mg/kg b.wt.)		3.67±0.18 ^{ab}	74.44±6.46 ^{ab}	2.90±0.19 ^{ab}	14.77±1.56 ^{ab}

The values are presented as mean ± S.E.

(a): Significant difference between treated and control groups at $p < 0.05$.

(b): Significant difference between the two treated groups at $p < 0.05$.

Table (2): Changes in the activities of the antioxidant enzymes in the liver of rats treated orally with fungicide for 3 months.

Groups	Parameters	SOD	CAT	GSH-Px	GSH-R
		(U/mg protein)	(U/mg protein)	(mU/mg protein)	(mU/mg protein)
Control		102.55±7.68	11.53±0.95	162.70±12.65	110.25±8.95
(18.25 mg/kg b.wt.)		81.60±8.67 ^a	8.55±0.80 ^a	130.67±10.50 ^a	106.45±9.40
(36.50 mg/kg b.wt.)		52.45±5.66 ^{ab}	6.65±0.70 ^{ab}	43.90±5.50 ^{ab}	38.78±4.83 ^{ab}

The values are presented as mean ± S.E.

(a): Significant difference between treated and control groups at $p < 0.05$.

(b): Significant difference between the two treated groups at $p < 0.05$.

Table (3): Changes in the serum biochemical parameters of rats treated orally with fungicide for 3 months.

Groups	Parameters	AFP	ALT	AST	GGT	Alkaline phosphatase*	Acid phosphatase*
		(ng/ml)	(IU/L)	(IU/L)	(U/L)		
Control		1.25±0.08	38.80±2.15	78.12±5.60	18.80±1.60	85.78±7.18	34.26±3.50
(18.25 mg/kg b.wt.)		9.26±1.30 ^a	49.30±4.55 ^a	80.60±6.90	32.65±2.95 ^a	78.35±6.80	49.33±4.60 ^a
(36.50 mg/kg b.wt.)		12.85±2.64 ^{ab}	78.65±6.65 ^{ab}	98.85±7.23 ^{ab}	45.35±3.55 ^{ab}	44.55±5.65 ^{ab}	75.73±6.70 ^{ab}

*The levels of alkaline and acid phosphatases were presented as King Armstrong Units (KAU/L).

The values are presented as mean ± S.E.

(a): Significant difference between treated and control groups at $p < 0.05$.

(b): Significant difference between the two treated groups at $p < 0.05$.

Table (4): Changes in blood urea and creatinine levels of rats treated orally with Bromuconazole fungicide for 3 months.

Groups	Parameters	Urea (mg/100ml)	Creatinine (mg/100 ml)
		Control	7.10±0.65
(18.25 mg/kg b.wt.)	12.60±0.95 ^a	0.84±0.08	
(36.50 mg/kg b.wt.)	19.48±1.58 ^{ab}	1.36±0.09 ^{ab}	

The values are presented as mean ± S.E.

(a): Significant difference between treated and control groups at $p < 0.05$.

(b): Significant difference between the two treated groups at $p < 0.05$.

Effects on hepatic antioxidant enzyme activities:

The activities of superoxide dismutase (SOD), catalase (CAT), glutathione peroxidase (GSH-px) and glutathione reductase (GSH-R) were significantly inhibited by Bromuconazole administration (Table 2).

The serum level of alpha fetoprotein (AFP) and activities of alanine aminotransferase (ALT), aspartate aminotransferase (AST), γ -glutamyl transpeptidase (GGT), alkaline and acid phosphatases and blood urea and creatinine are presented in Tables (3,4). Bromuconazole administration showed significant increase of their values except that of alkaline phosphatase activity which was significantly decreased.

Effects on the histological structures of the investigated organs:

Liver:

Liver of rats exposed to low dose (1/20 LD₅₀) revealed thick, dull and opaque capsule. Hepatomegaly with grayish white foci scattered all over the hepatic surface was also observed.

Histologically, the hepatic capsule showed oedema of its wall and infiltrated with numerous numbers of eosinophils and lymphocytes. Vacuolar degeneration and coagulative necrosis of subcapsular hepatocytes was also seen (Fig. 1). Dysplasia of hepatocytes was recorded in three of examined rats.

Cytological changes revealed deeply basophilic cytoplasm with enlargement of nuclei. Some hepatocytes showed Mallory's like body intracytoplasmic acidophilic hyaline inclusions (Fig. 2).

Liver of rats exposed to high dose (1/10 LD₅₀) revealed gray to brownish colored mass of 1-3cm in diameter with areas of necrosis and hemorrhages. This mass was distributed in a focal manner in all hepatic lobules.

Histologically, disorganization of hepatic cords with dilatation of hepatic sinusoids was seen. Some lesions showed complete absence of hepatic sinusoids as well as central veins. The area of hepatoma showed apoptosis of hepatocytes with hemorrhages (Fig. 3).

Cytological changes, the hepatocytes showed deeply basophilic cytoplasm with condensation of nuclear chromatin. Binucleated cells, mitotic figures polymorphism of hepatocytes were noticed (Fig. 4).

Thyroid gland:

Thyroid gland of rats exposed to low dose (1/20 LD₅₀) showed mild enlargement in comparison with control group.

Histologically, the acini were lined by simple cuboidal epithelial cells with papillary infolding. The acini were also distended with deeply eosinophilic colloid with peripheral vacuolation of the colloid indicated resorption (Fig. 5).

On the other side thyroid gland of rats exposed to high dose (1/10 LD₅₀) showed large adenomatous lesions surrounded by fibrous connective tissue capsule.

Histologically, showed follicular pattern characterized by densely packed follicles of varying

size lined by single layer of epithelium. Some follicles appeared smaller than normal (micro-follicles) and contained scanty amount of colloid. On the other hand, large follicles with irregular shape (macro-follicles) were also seen and lined by squamous flattened epithelial cells (Fig. 6,a).

Some cases showed adenomatous structure with papillary pattern, characterized by follicles of varied size with complex branching papillary structures protruding into follicular lumens. The colloid in this type of adenoma appeared more basophilic than normal (Fig. 6,b).

Pancreas:

Pancreatic parenchyma of rats exposed to low dose (1/20 LD₅₀) showed atrophy of acini with prominent interlobular duct. The Langerhan's islet cells appeared similar to control group (Fig. 7).

The islets of Langerhan's of rats exposed to high dose (1/10 LD₅₀) revealed atrophy in comparison with the low dose group. The interlobular duct was prominent and contained eosinophilic materials. Pancreatic blood vessels revealed thickening of its wall. The aciner structure showed individual necrosis of its epithelial lining (Fig. 8).

Kidney:

Kidneys of rats exposed to low dose (1/20 LD₅₀) showed segmental glomerulonephritis characterized by proliferation of endothelial, mesangial cells and inflammatory cells infiltration. Renal tubules revealed degenerative changes of its tubular epithelial lining. Some tubules showed coagulative necrosis of epithelial lining with intra-luminal albumin casts (Fig. 9).

Kidneys of rats exposed to high dose (1/10 LD₅₀) showed collapsed glomeruli and thickening of glomerular basement membrane. The proximal tubules were dilated and lined by low cuboidal cells and some of them showed coagulative necrosis (Fig. 10).

Pathognomonic lesions of high dose (1/10 LD₅₀) exposed rats:

Renal pelvis:

Renal pelvis showed hyperplasia of its epithelial lining. Some transitional cells revealed vacuolation besides necrosis of the superficial epithelial layer (Fig. 11).

Urinary bladder:

Urinary bladder in most of examined cases appeared as sac of collected blood with congested serosa of blood vessels.

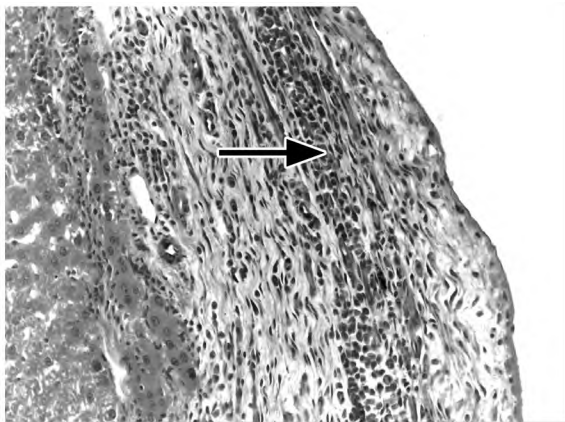


Fig. (1): Liver showing perihepatitis with eosinophils infiltration "arrow" (H & E, X 200).

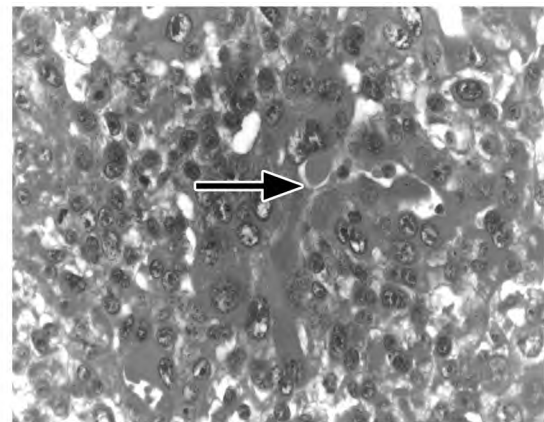


Fig. (2): Liver showing dysplasia of hepatocytes with intracytoplasmic inclusion (Mallory's body) "arrow" (H & E, X 200).

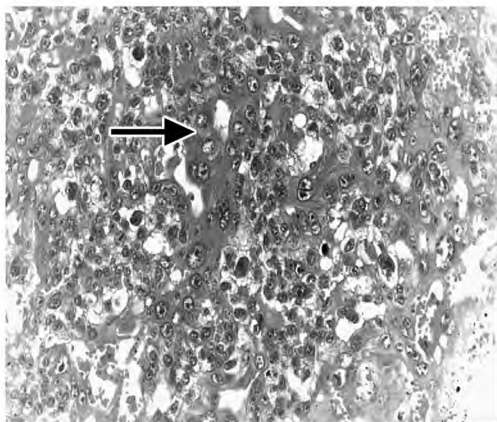


Fig. (3): Liver reveals hepatoma (hepatocellular carcinoma) which appeared in a focal manner with cellular atypia "arrow" (H & E, X 200).

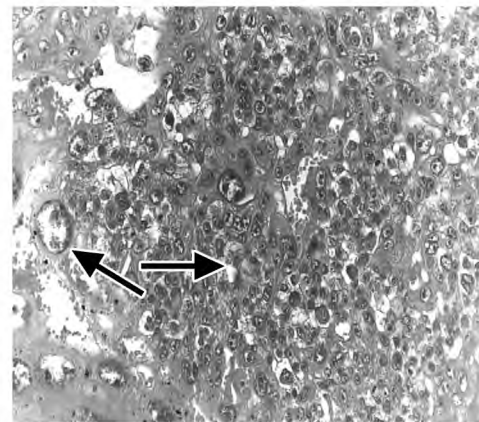


Fig. (4): Liver showing binucleated cells, mitotic figures, polymorphism of hepatocytes and karyomegalic changes "arrow" (H & E, X 200).

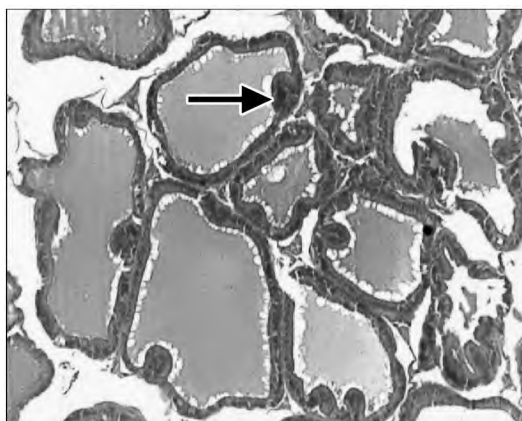


Fig. (5): Thyroid gland showing follicular cell hyperplasia "arrow" with varied size follicular spaces (H & E, X 200).

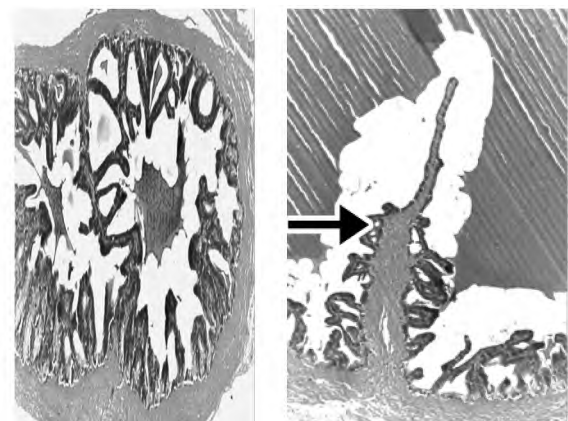


Fig. (6): (A): Thyroid gland showing adenomatous lesion with follicular pattern characterized by densely packed follicles of varying sizes (H & E, X 200).

(B): Thyroid gland showing complex branching papillary structures protruded into follicular lumens "arrow" (H & E, X 200).

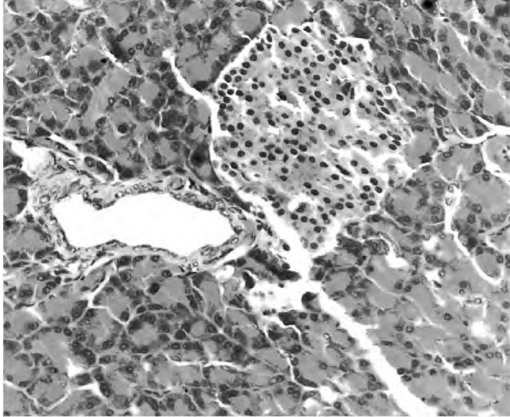


Fig. (7): Pancreatic gland showing individual cell necrosis within acini and normal Langerhan's islet cells (H & E, X 200).

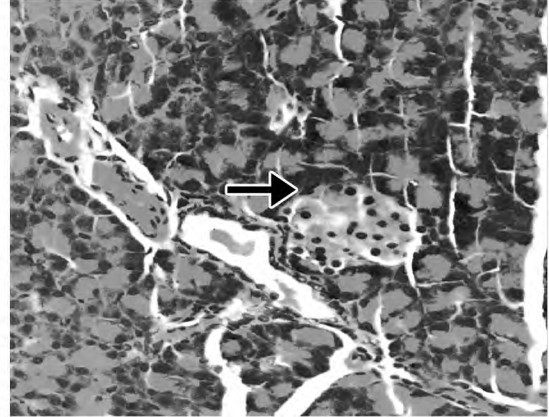


Fig. (8): Pancreas showing relative atrophy of Langerhan's islets "arrow" and thickening of blood vessels wall (H & E, X 200).

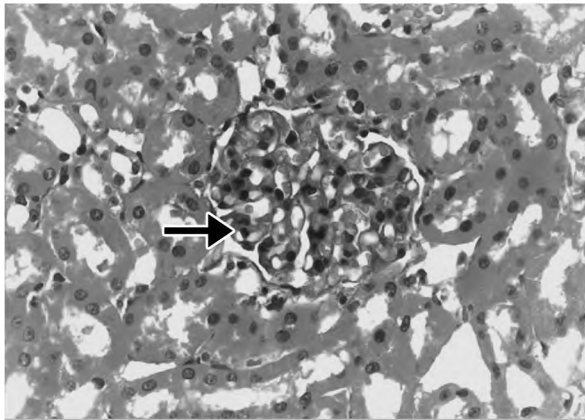


Fig. (9): Kidney showing segmental glomerulonephritis with necrobiotic changes of tubular epithelial lining "arrow" (H & E, X 200).

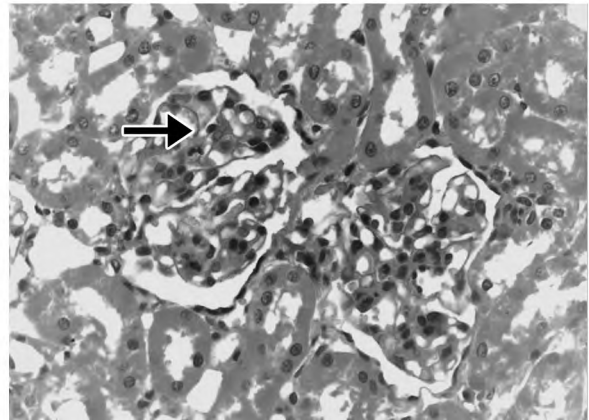


Fig. (10): Kidney showing thickening of glomerular basement membrane "arrow" with dilatation of capillaries tufts and degeneration of tubular epithelial lining "arrow" (H & E, X 200).

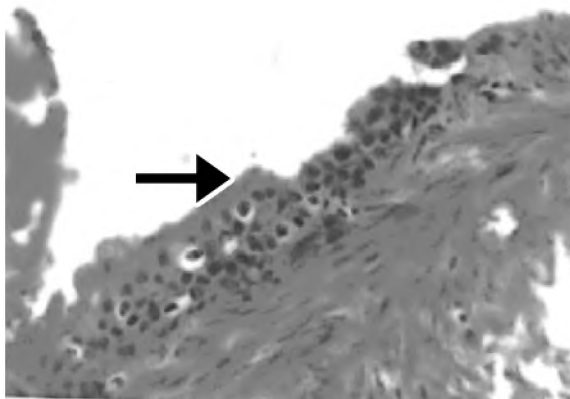


Fig. (11): Renal pelvis showing hyperplasia and vacuolation of its epithelial lining (H & E, X 200).

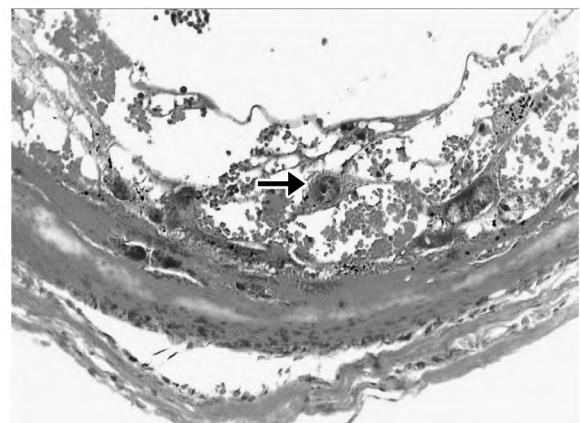


Fig. (12): Urinary bladder showing dispersion of its epithelial lining with formation of hemorrhagic spaces (H & E, X 200).

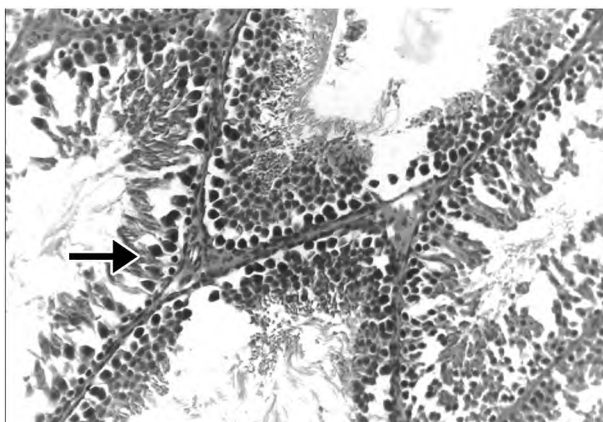


Fig. (13): Seminiferous tubules showing degenerative changes of spermatogenic cells "arrow" (H & E, X 200).

Histologically, the transitional epithelial lining was dispersed in the form of spindle cells with large oval or ovoid nucleus. Hemorrhagic spaces were detected in between the epithelia. Some epithelia were migrated in between the edematous muscular bundles (Fig. 12).

Testis:

Testis of rats exposed to low dose ($1/20$ LD₅₀) showed various degrees of degenerative changes as well as desquamation of spermatogenic cells. Some tubules revealed cessation of spermatogenesis as evidenced by their lining with single or double spermatogonial cell layers only (Fig. 13).

Testis of rats exposed to high dose ($1/10$ LD₅₀) revealed thickening of seminiferous tubules wall with degenerative changes of spermatogenic cells. Coagulation of spermatids in the form of eosinophilic structureless globules was noticed. Vacuolation of sertoli cells was also seen (Fig. 14).

Discussion

The present investigation was performed to explore the precise long-term toxic effects of Bromuconazole fungicide exposure in male rats.

Bromuconazole caused an increase in the liver and kidney content of MDA as a measure of lipid peroxidation and oxidative stress which accompanied with necrobiotic changes, dysplasia of hepatocytes and damage of renal tubules and urinary passages. All changes in the chemical parameters and liver tissue were reflected as cessation of seminiferous tubules function.

In the liver, superoxide dismutase (SOD), catalase (CAT), glutathione peroxidase (GSH-px) and

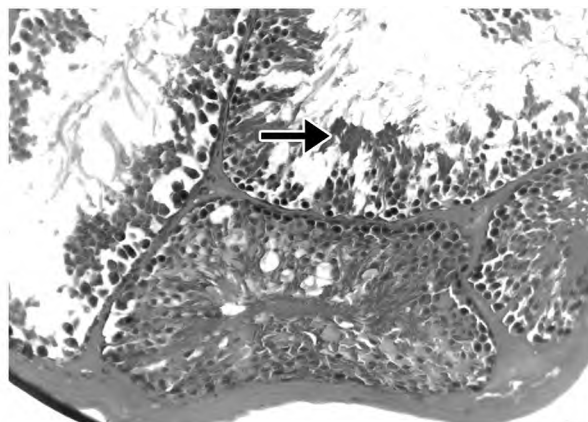


Fig. (14): Seminiferous tubules showing coagulation of spermatids in the form of eosinophilic structureless globules "arrow" and vacuolation of Sertoli cells "arrow" (H & E, X 200).

glutathione reductase (GSH-R) activities and reduced glutathione (GSH) concentration were decreased compared to those of controls. In consistent with our results, Ketoconazole has been reported also to cause liver damage in exposed rats where the liver showed massive centrilobular necrosis [8,26].

Similar to the recorded Bromuconazole induced hepatoma in our results, fenbuconazole (A triazole fungicide) exposure of mice has been associated with increased incidences of liver adenomas with a dose-dependant increase in liver microsomal cytochromes b5 and P450 [10,27]. Also, the increased liver weights, hepatocyte hypertrophy and changes in hepatic tissue nucleic acids content reported herein confirmed the previous studies on other triazoles [9,28].

In mammalian systems, conazoles modulate many CYP enzymes involved in the metabolism of xenobiotics, sterols, steroids, vitamin D, and other xenobiotics [5-10]. Inhibition of CYP26, a P-450 enzyme, has been demonstrated in patients with acute promyelocytic leukemia after treatment with fluconazole [29]. Therefore, most of these compounds are considered hepatotoxic in experimental animals due to induction and/or inhibition of mammalian hepatic cytochrome P450s (CyPs) [7,8,28].

Bromuconazole-induced toxicity could be attributed to the production of reactive oxygen species as well as depressing endogenous antioxidants and enhancing lipid peroxidation [30]. This observation is the possible explanation for the inhibition of SOD activity by Bromuconazole obtained in our experiments.

Moreover, liberation of liver enzymes; alanine aminotransferase (ALT), aspartate aminotransferase (AST), alkaline and acid phosphatases in serum, and the histopathological changes in liver and kidney tissues may be resulted from overproduction of reactive oxygen species and decreased efficacy of inhibitory and scavenging enzyme systems, SOD, CAT, GSH-Px and GSH-R, resulting in oxidative tissue damage. In addition, the decrease in GSH level in livers and kidneys confirms the involvement of reactive oxygen species in Bromuconazole-induced tissue damage. Lipid peroxidation may have also contributed to the decrease in intracellular GSH, since 4-hydroxynonenal, a major product of membrane peroxidation, can also react with GSH to yield inactive thioether derivatives [31].

Significantly increased serum activities of alanine aminotransferase (ALT), aspartate aminotransferase (AST), γ -glutamyl transpeptidase (GGT), alkaline and acid phosphatases, blood levels of urea and creatinine and decreased alkaline phosphatase activity indicated the incidence of hepatocellular injury and nephrotoxicity [32-34].

The present work displayed hepatocellular carcinoma as a dose-dependant lesion. The latter was accompanied by increased serum biochemical parameters especially ALT in a dose-dependant manner. The rise in serum ALT and AST activities may be a result of sudden change in tissue permeability, cell fragmentation or from a specific phase of progressive cellular damage [35].

The cytotoxic effect of any oncogen, if it persists, is to present a continual suppression on normal hepatocytes, however, new regenerating cells that survive may not be so inhibited; a new hepatocytes population develops that is resistant to the toxic property of the oncogen and free to proliferate [36,37]. Mallory's body was frequently seen in hepatocytes surrounding hepatocellular carcinoma (HCC). Stumptner et al. [38] described intracytoplasmic hyaline bodies resemble inclusions in hepatocellular carcinoma cells.

Our histological investigation revealing glomerulonephritis and degeneration of tubular epithelial lining with intraluminal eosinophilic casts are completely in agreement with recordings of Milutinovic et al. [37]. Also, the recorded renal pelvis and urinary bladder epithelial lining hyperplasia and testicular degeneration especially at the higher dose are consistent with those mentioned by EPA [11] in rats after flusilazole (A triazole fungicide)

oral treatment at 300mg/kg bw/day for 2 weeks. Therefore, the elevation of blood urea and creatinine level may be due to the renal lesions.

Bromuconazole treatment caused damage to spermatogenic and Sertoli cells and significantly decreased the sperm density in the testes. Oishi [39] and Kadalamani [40] suggested the possible mechanisms of testicular changes to direct inhibition of the respiratory functions of Sertoli cell mitochondria in rat testis and/or to the direct gonadotoxic effect on germinal layers of seminiferous tubules. Andersson et al. [41] stated that the association of decreased spermatogenesis and impaired Leydig cell function might reflect a disturbed paracrine communication between the seminiferous epithelium and the Leydig cells, triggered by distorted function of the seminiferous epithelium.

Bromuconazole-induced thyroid hyperplasia and adenomatous tumors in our results could be attributed to interference with the regulatory cycle of thyroid function leading to compensatory over growth of the thyroid (adaptation hyperplasia), whereby secretion of the thyroid hormone is maintained at about normal level as well as hyperplasia of islet of Langerhan's [42]. In addition, these carcinogenic growths may be resulted following radical disturbance of the hormonal balance [43]. Also, it may be the result of bromuconazole conversion via prostaglandin H synthase (PHS) to a mutagenic intermediate and/or the generation of reactive metabolites by thyroid peroxidase or PHS [44].

Tumor-associated antigens (such as AFP) are proposed as predictive markers of hepatocellular carcinoma cells disseminated into the circulation and for metastatic recurrence [45]. The significantly increased serum level of AFP in our results is supported by the presence of multiple microscopic foci of hepatocellular carcinoma seen in liver and cellular hyperplasia of renal pelvis, urinary bladder, thyroid gland and pancreas and confirms the carcinogenic potential of this fungicide. These results are comparable with those described by Kolbye [43]; EPA [11]; WHO [27]; Juberg et al. [10] and Sun et al. [28].

Conclusion:

The present study confirms the involvement of reactive oxygen species in Bromuconazole-induced toxicity, since the level of lipid peroxidation product (MDA) was increased with reduction of hepatic and renal glutathione contents of these organs and a consequent histopathological alteration in all

investigated organs. In addition, the activities of hepatic antioxidant enzymes and serum biochemistry were disturbed. Moreover, the serum AFP was increased suggesting a carcinogenic potential of this fungicide on prolonged exposure.

References

- 1- GUPTA P.K. and AGGARWAL M.: Toxicity of fungicides. In: Toxicology, Gupta R.C. (Ed.), 1st ed., 587-601, 2007, Elsevier, 978-0-12-370467-2, New York.
- 2- BUCHENAUER H.: Mechanism of action of triazolyl fungicides and related compounds. In Modern selective fungicides: Properties, applications, mechanisms of action, (H. Lyr, Ed.), pp. 205-231, 1987, Wiley, New York.
- 3- FILIPOV M.N. and LAWRENCE D.A.: Developmental Toxicity of a Triazole Fungicide: Consideration of Interorgan Communication Toxicol. Sci., 62: 185-186, 2001.
- 4- MENEGOLA E., BROCCIA M.L., RENZO F.DI, MASSA V. and GIAVINI E.: Study on the common teratogenic pathway elicited by the fungicides triazole-derivatives. Toxicology in Vitro, 19: 737-748, 2005.
- 5- SUZUKI S., KURATA N., NISHIMURA Y., YASUHARA H. and SATOH T.: Effects of imidazole antimycotics on the liver microsomal cytochrome P450 isoforms in rats: comparison of in vitro and vivo studies. Eur. J. Drug Metab. Pharmacokinet., 25: 121-126, 2000.
- 6- KOBAYASHI Y., SUZUKI M., OHSHIRO N., SUNAGAWA T., SASAKI T., TOKUYAMA S., YAMAMOTO T. and YOSHIDA T.: Climbazole is a new potent inducer of rat hepatic cytochrome P450. J. Toxicol. Sci., 26: 141-150, 2001.
- 7- NIWA T., INOUE-YAMAMOTO S., SHIRAGA T. and TAKAGI A.: Effect of antifungal drugs on cytochrome P450 (CYP) 1A2, CYP2D6, and CYP2E1 activities in human liver microsomes. Biol. Pharm. Bull., 28: 1813-1816, 2005.
- 8- TULLY D.B., BAO W., GOETZ A.K., BLYSTONE C.R., REN H., SCHMID J.E., STRADER L.F., WOOD C.R., BEST D.S., NAROTSKY M.G., WOLF D.C., ROCKETT J.C. and DIX D.J.: Gene expression profiling in liver and testis of rats to characterize the toxicity of triazole fungicides. Toxicol. Appl. Pharmacol., 215 (3): 260-73, 2006.
- 9- SUN G., THAI S.-F., LAMBERT G.R., WOLF D.C., TULLY D.B., GOETZ A.K., GEORGE M.H., GRINDSTAFF R.D., DIX D.J. and NESNOW S.: Fluconazole-induced hepatic cytochrome P450 gene expression and enzymatic activities in rats and mice. Toxicol. Lett., 164: 44-53, 2006.
- 10- JUBERG D.R., MUDRA D.R., HAZELTON G.A. and PARKINSON A.: The effect of fenbuconazole on cell proliferation and enzyme induction in the liver of female CD1 mice. Toxicol. Appl. Pharmacol., 214 (2): 178- 87, 2006.
- 11- EPA: Flusilazole. Pesticides residues in food: Toxicological and Environmental evaluations, Part II, Environmental Protection Agency Office of Pesticide Programs Registration Division, Fungicide Branch, 1200 Pennsylvania, Avenue NW, Washington, 1995.
- 12- NODA S., MUROI T., TAKAKURA S., SAKAMOTO S., TAKATSUKI M., YAMASAKI K., TATEYAMA S. and YAMAGUCHI R.: Ability of the Hershberger assay protocol to detect thyroid function modulators. Arch. Toxicol., 79 (11): 627-35, 2005.
- 13- WORTHING C.R. and S.B. WALKER: The pesticide manual, 10th Ed. a world Compendium, British Crop Protection Council., Pp. 124-125, 1994.
- 14- EPA: Bromuconazole. Pesticide Fact Sheet, Environmental Protection Agency Office of Pesticide Programs Registration Division, Fungicide Branch, 1200 Pennsylvania, Avenue NW, Washington, 2002.
- 15- ALBRO P.W., CORBET J.T. and SCHROEDER J.L.: Application of the thiobarbituric assay to the measurement of lipid peroxidation products in microsomes. J. Biochem. Biophys. Methods, 13: 185, 1986.
- 16- CHANARIN H.: "Laboratory Haematology: An Account of Laboratory Techniques" Churchill Livingstone, New York, Pp. 108-109, 1989.
- 17- ABELEV G.L.: Alpha- fetoprotein in oncogenesis and its association with malignant tumors. Adv. Cancer Res., 14: 295-358, 1971.
- 18- BERGMAYER H.U., SCHEIBE P. and WAHLE FIELD A.W.: Optimization of methods for aspartate aminotransferase and alanine aminotransferase. Clin. Chem., 24: 58-61, 1978.
- 19- PSIJN J.P.: Kinetic determination of γ -glutamyl transpeptidase activity. Clin. Chim. Acta., 35: 329, 1971.
- 20- BELFIELD A. and GOLDBERG D.M.: Calorimetric determination of alkaline phosphatase activity. Enzyme, 12: 561-568, 1971.
- 21- BABSON A. L. and READ A.P.: Calorimetric determination of acid phosphatase. Am. J. Clin. Pathol., 32: 89, 1959.
- 22- PATTON C.J. and CROUCH S.R.: Calometric determination of urea. Anal. Chem., 49: 464-469, 1977.
- 23- FOSSATI P., PRENCIPE L. and BERTI G.: Use of 3,5-dichloro-2-hydroxybenzenesulfonic acid/4 - aminophenazone chromogenic system in direct enzymic assay of uric acid in serum and urine. Clin. Chem., 26 (2): 227-231, 1980.
- 24- BANCROFT J.D. and COOK H.C.: Manual of histological techniques. 1st ed. Churchill livingstone, London and NewYork, 1993.
- 25- SNEDECOR G.W. and COCHRAN W.G.: Statistical Methods, Eighth Edition, Iowa State University Press, 1989.
- 26- ACOSTA D.Jr. and RODRIGUEZ: Comparison of ketoconazole and fluconazole-induced hepatotoxicity in a primary culture system of rat hepatocytes. Toxicology, Feb 6; 96 (2): 83-92, 1995.
- 27- World Health Organization (WHO): Joint Meeting of Food and Agriculture Organization of United Nations and World Health Organization (Lyon, France, 22 Sep-1 Oct., 1997); Fenbuconazole: Toxicological and Environmental Evaluation, Monograph, 930: 87-105, 1997.
- 28- SUN G., THAI S.-F., TULLY D.B., LAMBERT G.R., GOETZ A.K. WOLF D.C., DIX D.J. and NESNOW S.: Propiconazole-induced cytochrome P450 gene expression and enzymatic activities in rat and mouse liver. Toxicol. Lett., 155: 277-287, 2005.

- 29- VANIER K.L., MATTIUSSI A.J. and JOHNSTON D.L.: Interaction of all-trans-retinoic acid with Fluconazole in acute promyelocytic leukemia. *Journal of Pediatric Hematology and Oncology*, 25: 403-404, 2003.
- 30- SHCHEPETKIN I.A., CHERDYNTSEVA N.V. and KAGIJA V.T.: Effect of sanazole and metrinidazole on production of reactive oxygen species by macrophages. *Antibiot Khimioter*, 48 (3): 7-10, 2003.
- 31- ESTERBAUER H., SCHRAUR R.J. and ZOLLNER H.: Chemistry and biochemistry of 4-hydroxynonenal, malondialdehyde and related aldehydes. *Free radic. Biol. Med.*, 11: 81-128, 1991.
- 32- KANEKO J.J., HARVERY W.J. and MICHAEL L.B.: *Clinical Biochemistry of Domestic Animals*. 5th Ed. San Diego, London, Boston, New York, 1997.
- 33- SELMANOGLU G., BARLAS N., SONGUR S. and KOCKAYA E.A.: Carbendazim- induced haematological, biochemical and histopathological changes to the liver and kidney of male rats. *Hum. Exp. Toxicol.*, 20 (12): 625-30, 2001.
- 34- HAGAR H.H.: The protective effect of taurine against cyclosporine induced oxidative stress and hepatotoxicity in rats. *Toxicol. Lett.*, 151 (2): 335-43, 2004.
- 35- KRISTENSEN S.R.: Mechanisms of cell damage and enzyme release. *Dan. Med. Bull.*, 41: 423-433, 1994.
- 36- CHEVILLE N.F.: *Cell Pathology*. 2nd Ed. Pp. 681, 1983.
- 37- MILUTINOVIC A., ZIVIN M., ZORC-PLESKOVIC and SEDMAK B.: Nephrotoxic effects of chronic administration of microcystins. *Toxicon.*, 42 (3): 281-8, 2003.
- 38- STUMPTNER C., HEID H. and FUCHSBICHLER A.: Analysis of intracytoplasmic hyaline bodies in a hepatocellular carcinoma. *Am. J. Pathol.*, 154: 1701-1710, 1999.
- 39- OISHI S.: Effects of phthalic acid esters on testicular mitochondrial function in the rat. *Arch. Toxicol.*, 64 (2): 143-149, 1990.
- 40- KADALMANI B., GIRIJA FARIDHA A. and AKBAR-SHA M.A.: Male reproductive toxic effects of carbendazim: Hitherto unreported target in the testis. *Indian J. Exp. Biol.*, 40 (1): 40-44, 2002.
- 41- ANDERSSON A.M., JORGENSEN N., FRYDELUND-LARSEN L., RAIPERT-DE MEYTES E. and SKKE-BAEK N.E.: Impaired Leydig cell function in infertile men: A study of 357 idiopathic infertile men and 318 proven fertile controls. *J. Clin. Endocrinol. Metab.*, 89 (7): 3161-3167, 2004.
- 42- STEINHOFF D., WEBER H., MOHR U. and BOEHME K.: Evaluation of amitrole (aminotriazole) for potential carcinogenicity in orally dosed rats, mice, and golden hamsters. *Toxicol. Appl. Pharmacol.*, 69 (2): 161-9, 1983.
- 43- KOLBYE A.C.: Proposed research and regulatory plan to improve risk evaluation concerning factors contributing to the incidence of cancer and genetic damage. *Reg. Toxicol. Pharmacol.*, 2: 232-237, 1982.
- 44- KRAUSS R.S. and ELING T.E.: Macromolecular binding of the thyroid carcinogen 3-amino-1,2,4-triazole (amitrole) catalyzed by prostaglandin H synthase, lactoperoxidase and thyroidperoxidase. *Carcinogenesis*, 8 (5): 659-64, 1987.
- 45- QIN L.X. and TANG Z.Y.: Recent progress in predictive biomarkers for metastatic recurrence of human hepatocellular carcinoma: A review of the literature. *J. Cancer Res. Clin. Oncol.*, 10: 1432-1435, 2004.