

Official Reprint PDF

***Nigella sativa* Seeds Ameliorate the Testicular Toxicity of Colchicine Repeated Use in Adult Male Albino Rats: A Biochemical and Histopathological Study**

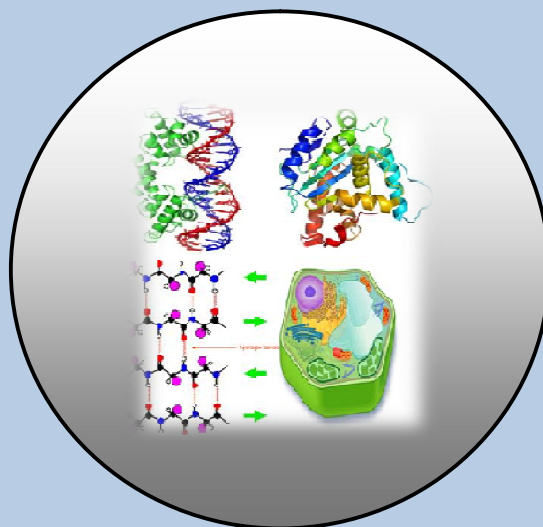
By

**G. M. G. Shehab, S. S. Elshama,
A. E. El-Kenawy and H. H. Osman**

ISSN 0970-4973 (Print)

ISSN 2319-3077 (Online/Electronic)

J. Biol. Chem. Research
Volume 31 (1) 2014 Pages No. 146-163



**Journal of
Biological and
Chemical Research**

(An International Journal of Life Sciences and Chemistry)

Indexed, Abstracted and Cited: Index Copernicus International (Europe), Chemical Abstract Services (U.S.A.), Research Bible (Japan), Directory of Research Journals Indexing (DRJI), Indian Science.in, Database Electronic Journals Library (Germany), Open J-Gate, Google Scholar, J Gate e-Journal Portal, Info Base Index International Impact Factor Services (Singapore) and Eye Source

Published by Society for Advancement of Sciences®



Dr. G.M.G. Shehab

[http:// www.jbcr.in](http://www.jbcr.in)

jbicrchemres@gmail.com

info@jbcr.in

RESEARCH PAPER

Received: 20/11/2013

Revised: 28/12/2013

Accepted: 30/12/2013

***Nigella sativa* Seeds Ameliorate the Testicular Toxicity of Colchicine Repeated Use in Adult Male Albino Rats: A Biochemical and Histopathological Study**

**G. M. G. Shehab^{1,5}, S. S. Elshama^{2,6},
A. E. El-Kenawy^{3,7} and H. H. Osman^{4,8}**

Department of Medical Biochemistry¹, Department of Forensic Medicine and Clinical Toxicology², Department of Pathology³ and Department of Anatomy⁴, College of Medicine, Taif University, kingdom of Saudi Arabia. Department of Biochemistry, Faculty of Agriculture, Cairo University, Egypt⁵. Department of Forensic Medicine and Clinical Toxicology, Suez Canal University, Egypt⁶. Department of Molecular Biology. Genetic Engineering and Biotechnology Inst., Menoufiya University, Egypt⁷. Department of Anatomy, Al-Azhar University, Egypt⁸.

ABSTRACT

*Colchicine has been used to treat many diseases for several decades. It has a narrow therapeutic index, with no clear-cut distinction between nontoxic, toxic, and lethal doses, causing substantial confusion among clinicians. The symptoms of gastrointestinal toxicity of colchicine have been reported for patients on full therapeutic doses and associated with high mortality rate. Recently, it has been reported that colchicine induces overproduction of reactive oxygen species (ROS) and decreases efficiency of antioxidant defenses. Overproduction of ROS can be noxious to sperm and being associated with male infertilities. The aim of the present study was to investigate the testicular toxicity induced by continual use of colchicine, and the role of *Nigella sativa* seeds as a natural potent antioxidant on the modulation of this toxicity. 60 adult male albino rats divided into three equal groups (each n = 20).*

The first group healthy untreated rats; served as negative control(NCG), the second group was given colchicine orally (2mg/kg/day); served as positive control group(PCG), and the third group was given 2mg/kg/day of colchicine and 1g/kg/day of aqueous suspension of Nigella sativa seeds powder; served as N. sativa treated group (NSG). Administration of the drug and the aqueous suspension were achieved by gastric gavage for 12 weeks. Testicular toxicity was investigated by assessment of biochemical and histopathological changes. The biochemical investigations revealed that the administration of colchicine reduced the activity of antioxidant enzymes: catalase (CAT), glutathione peroxidase (GPx), and superoxide dismutase (SOD). Also, reduced the total amount of glutathione (GSH) and the level of plasma testosterone (TST), but increased the malondialdehyde (MDA) content and nitric oxide (NO) in rat testis tissues when compared with the NCG. The administration of N. sativa with colchicine prevented the depletion of antioxidant enzymes; CAT, GPx, and SOD, the total GSH and TST, and inhibited the increase of MDA and NO when compared with PCG.

The biological and histopathological investigations revealed that repeated use of colchicine decreased the testes and the seminal vesicles weight, the normal sperm count, sperm motility and viability. Also, colchicine induced testicular toxicity manifested by marked degeneration of seminiferous tubules germinal cells, interstitial cells of Leydig and spermatid in the form of irregular acrosomal cap with degenerated sperms, swollen vacuolated mitochondria and periphery clumped chromatin particles in cytoplasm of spermatogonia with low positive reaction with Periodic acid Schiff (PAS) stain. The administration of N. sativa with colchicine ameliorated the toxicity effects of the drug. It is clear from this study that the continual use of colchicine has a testicular toxicity, which can be ameliorated by the administration of N. sativa seeds. Thus, we can recommend the consumption of N. sativa as a safe, natural and potent antioxidant for patients who use colchicine drug repeatedly as a protective agent against oxidative stress induces by the drug.

Keywords: Colchicine, Nigella sativa, Oxidative stress, Toxicity and Testis.

INTRODUCTION

Colchicine is a drug with both a narrow therapeutic-toxicity window and a marked variability between individuals in drug disposition as well as potentially serious drug– drug interactions (Terkeltaub, 2005). Colchicine has been used to treat gout for more than 2000 years, and pseudogout and familial Mediterranean fever (FMF) for several decades. It also has been used for treatment of primary biliary cirrhosis amyloidosis and condyloma acuminata (Güven et al., 2002). Moreover, colchicine has been reported to protect against a variety of hepatotoxic insults and improve survival in a clinical trial for alcoholic cirrhosis (Maxwell et al., 2002). The symptoms of gastrointestinal toxicity of colchicine such as nausea, vomiting, diarrhea and abdominal pain are seen in 80% of patients on full therapeutic doses and are used as the clinical endpoint in dose titration (Milne and Meek, 1998). It has been proved that colchicine therapy in Behcet's disease (an inflammatory disorder of an unknown cause) has a potential effect on

increased protein oxidation and lipid peroxidation, owing to the overproduction of reactive oxygen species (ROS) and decreased efficiency of antioxidant defenses (Gulbahar et al., 2007). Moreover, it has been reported that central administration of colchicine induced dysfunction and oxidative stress in rats (Kumar et al., 2006; Veerendra Kumar and Gupta 2002).

Oxidative stress occurs when the balance between reactive oxygen species (ROS) generating systems and antioxidants is disrupted towards an overabundance of ROS. Although, ROS serve as key signal molecules in physiological processes they also have a role in pathological processes. The production of ROS is a normal physiological process in various organs including the testis. Overproduction of ROS can be noxious to sperm and being associated with male infertilities. The excessive generation of ROS by abnormal spermatozoa, contaminating leukocytes and by a various type of pollutants has been identified as detrimental etiologies for male infertilities. ROS are generated by sperm and seminal leukocytes within semen and produce infertility by two key mechanisms. First, they damage the sperm membrane, decreasing sperm motility and its ability to fuse with the oocyte. Second, ROS can alter the sperm DNA, resulting in the passage of defective DNA (El-Tohamy, 2012).

Nigella sativa is a plant of *Ranunculaceae* family that grows spontaneously and widely in several Southern Mediterranean and Middle Eastern countries. Its seed has over 100 different chemical constituents including both fixed and essential oils, proteins, alkaloids and saponin. It can be concenter as an abundant source of all the essential fatty acids. Most of the biological activity of the seeds has been shown to be due to thymoquinone, the major component of the essential oil. The seeds of *Nigella sativa* or its oil have been used for medicinal purposes as a natural remedy for a number of illnesses and conditions such as: bronchial asthma, rheumatism, hypertension, diabetes, inflammation, cough, headache, eczema, fever and influenza (Ali and Blunden, 2003; Burits and Bucar, 2000; Singh et al., 2005). The seeds are characterized by a very low degree of toxicity (Ali and Blunden, 2003). Many researcher have reported the antioxidant activity of *Nigella sativa* (Abdel-Wahhab and Aly, 2005; Ali and Blunden, 2003; Burits and Bucar, 2000). Thus, the present study aimed to investigate the testicular toxicity that may induce by repeated use of colchicine, and the role of *nigella sativa* seeds on the modulation of this toxicity by assessing the biochemical and histopathological changes of adult albino rat testis.

MATERIAL AND METHODS

Preparation of colchicine and *N. sativa* seeds suspension

Cholchicine drug was obtained from El-Nasr pharmaceutical chemicals company (ADWIC) Abu-Zaabal Egypt in the tablet form. One tablet contains 500 microgram of active ingredient was dispersed in 5 ml distilled water.

Nigella sativa seeds were purchased from a local market, Taif, KSA. One gram of the seeds was added to 100 ml of distilled water, mixed and grinded by a blender. This was made for 5-6 intervals, 60 seconds each time, at room temperature until complete grinding and mixing to obtain a stock solution of crude suspension (Tekeoglu et al., 2007).

Animals and experimental design

Sixty adult male albino healthy rats weighing (150 ± 20 g) were used for this study. They were housed in air-conditioned, humidity-controlled animal room at College of medicine, Taif University. Rats had free access to water and food during the experimental period. The rats were caged in three equal groups (each $n=20$). The first group healthy untreated rats; served as negative control (NCG); each rat received 1ml of distilled water per day orally (via gavage) for 12 weeks. The second group was given colchicine orally (2mg/kg/day); served as positive control group (PCG) (Terkeltaub *et al.*, 2010) and the third group was given 2mg/kg/day of colchicine and 1000mg/kg/day of aqueous suspension of *Nigella sativa* seeds powder; served as *N. sativa* treated group (NSG) (Gali-Muhtasib *et al.*, 2006). Oral administration was achieved by gastric gavage. Rats of each group were euthanized at the end of the experimental period under anesthesia by administration of 0.5 cm of ketamine intraperitoneal. Testicular toxicity was investigated by assessment of biochemical and histopathological changes.

Ethical considerations

All animal experiments were carried out in accordance with the internationally accepted guidelines for the care and use of laboratory animals. Painful procedures were performed under anesthesia to avoid distress and pain. Our standards of animal care and administration met those required by applicable international laws and regulations.

Biochemical assessment

Preparation of tissue homogenate

The collected testes were grinded with liquid nitrogen in a mortar. The grinded tissues (0.5 g) were then homogenized immediately in 2mL 50mM phosphate buffer (pH 7.8) containing 1mM EDTA and 1% PVP. The homogenate was centrifuged under cooling at 15,000xg for 20 min, and the supernatant was stored in a deepfreeze until used for the determination of catalase (CAT), glutathione peroxidase (GPx), superoxide dismutase (SOD), the total amount of glutathione (GSH) and the content of malondialdehyde (MDA) and nitric oxide (NO). Protein content in the crude extracts was determined according to the Bradford's method (Bradford, 1976) with bovine serum albumin (BSA) as the standard.

Enzyme activity assays

CAT activity in the testis homogenate was measured by following the consumption of H_2O_2 using the method of Aebi (1984); SOD was assayed by measuring its ability to inhibit the photochemical reduction of nitroblue tetrazolium (NBT) using the method of Beauchamp and Fridovich (1971) and GPx activity was determined according to the method described by Sazuka *et al.* (1989).

Determination of lipid peroxidation, Nitric oxide (NO) and testicular glutathione (GSH):

Lipid peroxidation expressed as malondialdehyde (MDA) formation was assayed colorimetrically in testis homogenate according to the method described by Ohkawa *et al.*, (1979). The assay of nitrite/nitrate, as an indirect measure of NO production, was done according to the method described by Green *et al.*, (1982). Testicular glutathione (GSH) levels were determined according to Ellman (1959).

Estimation of plasma testosterone level

The thoracic cavity was opened and blood samples were collected directly after puncture of rat's hearts in the morning in order to minimize the diurnal variation of hormone levels. Collection of plasma was done by using heparin as an anticoagulant. The plasma was collected by centrifuging the samples for 15 minutes at 1000 xg within 30 minutes of collection. Assay of testosterone level was performed immediately according to the method of **Sakuma (2009)**.

Histopathological assessment

Semen analysis

Seminal content of epididymis was obtained by cutting of cauda epididymis using surgical blades and squeezed in a sterile clean watch glass. This content was diluted with normal saline on warm slide and thoroughly mixed to estimate the progressive motility. One drop of the suspension was smeared on a glass slide and stained by an equal drop of Eosin-nigrosin stain (1% eosin + nitrogen dissolved in 20.9% sodium citrate dehydrate buffer). The film is spread on clean slide and dried quickly on a hot plate to determine the percentage of sperm cell viability and morphological abnormalities such as abnormal head and tail (**Mori et al., 1991**). The haemocytometer pipette of erythrocyte was used for counting sperms. The diluted epididymal content (diluted with 100 ul eosin) was withdrawn up to mark 0.5 and the pipette was filled up to the mark by 2% aqueous solution of eosin. The eosin killed sperms so that counting could be accomplished as well as staining the sperm heads so that they were easier to be counted. The contents of the pipette were mixed and the sperms in five large squares (80 small squares) were counted using the high power of the light microscope. The sperm concentration per epididymis was calculated by the following equation:

$$\text{Sperm concentration / epididymis} = N/80 \times 400 \times 200 \times 10 \times 100$$

Where: N = Count Sperm number; 80 = Number of small square in five large squares; 400 = Total number of small squares in chamber; 10 = Depth of haemocytometer chamber; 200 = Dilution factor on pipette and 100 = Dilution factor of epididymal content (**Bearden et al., 2003**).

Histopathological Examination

Following the semen collection, the testes of rats were dissected out; its tissues were cut and immediately fixed in Bouin's fluid. It processed for preparation of paraffin blocks (paraffin method). Sections were cut by rotatory microtome and mounted on glass slides. The sections were stained by Hematoxylin & Eosin, Mallory and Periodic acid Schiff (PAS). The sections were examined by light microscope (Leica DM 1000) (**Drury and Wallington, 1980**).

Ultrastructural studies were done by Transmission Electron Microscope (TEM). Testicular tissue was cut into small pieces 1 mm thick and fixed in 4% formaldehyde in phosphate buffer solution (pH 7.2) for 3 hr at 4 °C, after which the tissues were removed and post fixed in buffered 2% osmium tetroxyde for one hour at 4°C. Post fixed tissues were rinsed in the buffer and dehydrated at 4°C through a graded series of ethanol. Then they were embedded in Epon Araldite mixture in labeled beam capsules. Ultrathin sections (50 nm thick) were cut, collected on naked copper-mesh grids and stained with uranyl acetate for 10-15 min and lead citrate for 5-10 min (**Bancroft and Gamble, 2002**).

Statistical analysis

Statistical analysis was performed using SPSS version 16. Variability of results was expressed as mean \pm SD. The significance of differences between mean values was determined using one way analysis of variance (ANOVA) test and followed by Tukey (H.S.D) test.

RESULTS

Biochemical results

In the present work, three groups of adult male albino were used. The first group healthy untreated rats; served as negative control (NCG), the second group was given colchicine orally (2mg/kg/day); served as positive control group (PCG), and the third group was given 2mg/kg/day of colchicine and 1g/kg/day of aqueous suspension of *Nigella sativa* seeds powder; served as *N. sativa* treated group (NSG). Data represented in **table (1)** indicates that administration of colchicine (PCG) significantly reduced the activity of antioxidant enzymes: catalase (CAT), glutathione peroxidase (GPx), and superoxide dismutase (SOD). Also, significantly reduced the total amount of glutathione (GSH) and the level of plasma testosterone (TST), but increased significantly the malondialdehyde (MDA) content and nitric oxide (NO) in rat testis tissues when compared with the negative control group (NCG). The administration of *N. sativa* with colchicine (NTG) prevented the depletion of antioxidant enzymes; CAT, GPx, and SOD, the total GSH and TST, and inhibited the increase of MDA and NO when compared with the PCG.

Biological and histopathological results

Data in **table (2)** represented the effect of the treatment with colchicine alone or with *N. sativa* on the testes weight, the seminal vesicles weight and semen analysis. The Mean \pm SD data indicated that the administration of colchicine (PCG) significantly reduced the testes weight and the seminal vesicles weight compared with the NCG. Also, a significant decrease in the normal sperm count, sperm motility and viability were observed in the PCG compared with the NCG. The administration of *N. sativa* with colchicine (NTG) prevented the decrease of testes weight and the seminal vesicles weight and improved the semen quality and quantity when compared with the PCG.

Testicular histopathological findings by light microscope

Examination of testicular tissues of NCG rats showed normal structure of seminiferous tubules, basement membrane, germ cells, interstitial tissue, interstitial cells of Leydig and tunica albuginea (**Fig.1&2**) with normal sperms (**Fig.3**) and positive reaction of PAS (**Fig.4**). The examination of testicular tissues of PCG, which treated with colchicine alone, showed marked disorganization and necrotic germ cells lining of the seminiferous tubules, degenerated sperms and interstitial cells of Leydig, irregular thin basement membrane and tunica albuginea (**Fig.5&6**) with degenerated sperms (**Fig.7**) and low positive reaction of PAS (**Fig.8**). Testicular section of the NTG, which received colchicine and aqueous suspension of powdered *N. sativa* seeds showed marked recovery of germ cells lining of seminiferous tubules with normal sperms, normal interstitial cells of Leydig and basement membrane (**Fig.9&10**) with normal sperms (**Fig.11**) and positive reaction of PAS (**Fig.12**).

Testicular histopathological findings by electron microscope

Examination of testicular tissue ultrastructure in rats of the NCG showed normal histological structure of seminiferous tubule with various stages of spermatogenesis and interstitial of Lidge cells. The spermatogonia have two types, (A and B type). It lies on the basement membrane of seminiferous tubules. There are two types of spermatocytes (primary and secondary). The spermatids appear as rounded cells with large spherical nuclei and lightly stained cytoplasm. The Sertoli Cells are a large cell that extends from the basement membrane to the lumen of the seminiferous tubule (**Fig.13**). The ultrastructure examination of testicular tissues from the PCG rats showed thin irregular basal lamina of the seminiferous tubules with fibrous connective tissue and degenerative changes in the germinal cells. The cytoplasm of spermatogonia (type A and B) showed swollen vacuolated mitochondria, vascular endoplasmic reticulum and periphery clumped chromatin particles. There were degenerative changes of spermatid which appeared in the form irregular acrosomal cap (**Fig. 14**). The ultrastructure investigation of testis in rats of the third group (NTG) showed an improvement of histopathological changes of testis which manifested by normal basal lamina of seminiferous tubules, normal interstitial cells of Leydig and lack of degenerative changes in seminiferous tubules. There were marked improvement of germinal cells lining of seminiferous tubules particularly in primary spermatocytes and spermatids (**Fig.15**).

Semen analysis of rats in the first group (NCG), showed normal shaped sperms (**Fig.16. A**). in contrast, the second group rats (PCG) showed abnormal shaped sperms such as, thin elongated head, club-shaped head, incorrect head-neck connection, tailless head, headless tail, bent mid-piece and curved mid piece (**Fig.16.B**), while in the case of the semen of third group (NTG) rats showed improvement in reduction of abnormal shaped sperms (**Fig.16.C**).

DISCUSSION

Colchicine has been used to treat many diseases for several decades. It has a narrow therapeutic index, with no clear-cut distinction between nontoxic, toxic, and lethal doses, causing substantial confusion among clinicians. It has been shown to protect against a variety of hepatotoxic insults and improve survival in a clinical trial for alcoholic cirrhosis. In contrast, the symptoms of gastrointestinal toxicity of colchicine have been reported for patients on full therapeutic doses and associated with high mortality rate. Moreover, it has been reported that colchicine has a potential effect on increased protein oxidation and lipid peroxidation, owing to the overproduction of reactive oxygen species (ROS) and decreased efficiency of antioxidant defenses (**Gulbahar et al., 2007**). The excessive generation of ROS in the male reproductive tract has become an actual concern because of their probable harmful effects on physical properties of sperm quality (**Paick, 2003; Sharma and Agarwal, 1996**). Recently, the sperm damage as a result of oxidative stress has been documented to be a significant contributing feature in about 80% of male subfertility cases (**El-Tohamy, 2012**).

In the current study we investigated the testicular toxicity that may induce by repeated use of colchicine and the role of *N. sativa* seeds on the modulation of this toxicity by assessing the biochemical and histopathological changes of adult albino rat testis.

The choice of *N. sativa* was based on its antioxidant activity that has been reported by many researchers (**Abdel-Wahhab and Aly, 2005; Ali and Blunden, 2003; Burits and Bucar, 2000**), and its very low degree of toxicity (**Ali and Blunden, 2003**).

Antioxidant enzymes such as CAT, SOD and GPx and preventive antioxidants such as GSH are the first line of defense against ROS. Oxidative stress occurs when the balance between reactive oxygen species (ROS) generating systems and antioxidants is disrupted. Overproduction of ROS leads to lipid peroxidation, protein oxidation and DNA oxidation. Therefore, in the present study the activities of CAT, SOD, GPx antioxidant enzymes and the levels of GSH and MDA in rat testis tissue were studied to explore the toxicity effects of colchicine and the modulation effect of *N. sativa* seeds against this toxicity.

The biochemical investigation revealed that administration of colchicine significantly reduced the activity of antioxidant enzymes: CAT, SOD and GPx and reduced the total amount of GSH. On the other hand, colchicines increased significantly the MDA content and NO in rat testis tissues when compared with the negative control group (NCG). It is clear from these results that colchicines disrupted the balance between ROS generating systems and antioxidant agents, which led to overproduction of ROS in rat testis tissues. The overproduction of ROS led to lipid peroxidation indicated by an increase in MDA content, which in turn led to cell damage. These results were in agreement with **Gulbahar et al., (2007)**. The administration of *N. sativa* with colchicine (NTG) prevented the depletion of antioxidant enzymes: CAT, SOD, and GPx, and the total GSH, and inhibited the increase of MDA and NO when compared with the PCG.

The present study demonstrated a reduction in plasma testosterone level as a result of colchicine treatment. This result was in agreement with **Creasy (2001)**, who showed that male reproductive system toxicity may result in reduction of sperm output or reduction of testosterone secretion from the testis, and quality of the sperm available for fertilization may also be impaired. He indicated a relationship between body weight reduction of rat due to colchicine intoxication, fat deposition and decrease of testosterone level.

The results of the colchicine effect on the testes weight, the seminal vesicles weight and semen analysis revealed a significant reduction in the testis weight and the seminal vesicles weight compared with the NCG. Also, a significant decrease in the normal sperm count, sperm motility and viability were observed in the PCG compared with the NCG. The administration of *N. sativa* with colchicine (NTG) ameliorated these adverse effects. These results were in agreement with **Wahba, (2011)**, who found that pretreatment with *N. sativa*, linseed and celery oil exhibits a protective effect against testicular injury induced by sodium valproate in male rats. **Allard et al., (1993)** indicated that testicular reduction weight is due to decrease of germ cells number and volume of other testicular compartments such as interstitial and seminiferous epithelium.

According to **Ohtani et al., (2004)**, the weight of testis is the most sensitive parameter indicating the sperm toxicity and this is consistent with the current study.

The histopathological investigations revealed that colchicine has a potential testicular toxicity which characterized as marked degeneration of germinal cells of the seminiferous tubules, sperms, spermatid and interstitial cells of Leydig, irregular thin basement membrane and tunica albuginea with low positive reaction of PAS. This result is consistent with the result obtained by **Nabila (2006)**.

Our results revealed that regular use of colchicine led to damage of seminiferous tubules with germ cell loss and then defect of spermatogenesis causing low normal sperm count, increase of abnormal sperm number, decrease of sperm motility and viability, increase of abnormal shaped sperms and acrosome of testicular spermatids. This is consistent with **Harris and Gillet (1998)**.

According to **Hess and Nakai (2000)**, sperm morphogenesis is a complex process. Germ and Sertoli cells contain numerous microtubules which are essential for normal morphogenetic processes of spermatogenesis. Colchicine interacts with microtubules inducing sperm structural abnormalities. **El Shenawy et al., (2008)**, confirmed that colchicine intoxication induced testicular toxicity due to oxidative damage because the high lipid content of the reproductive organs such as testis makes it particularly susceptible to free radicals mediated insult.

Finkelstein et al., (2010), explained that histopathological changes of testis depending on colchicine toxicity due to arrest of cell division in metaphase by intervention with spindle fibers formation because of mitotic inhibition property of colchicine. It is taken up equally by all cells except highest cell turnover such as testicular cells which have the greatest mitotic activity and then it is more affected. **Brncic et al., (2001)**, indicated that mechanism of colchicine toxicity is due to its binding selectively and reversibly to 65 subunits of microtubules, altering cellular processes such as cell shaping, division, mobility and ability to exhibit phagocytosis. This is in contrast with **Klitschar et al., (1999)** who refereed that mechanism of toxicity is unrelated to binding microtubules.

Results of the current study showed an improvement in all the investigated parameters in the third group (NTG), which administered with *N. sativa* seeds with colchicines compared with the PCG. The protection effect of *N. sativa* seeds against testicular toxicity of colchicine may be due to its antioxidant action and free radical scavenger capacity, which may be due to its main constituent thymoquinone which possesses an important analgesic, anti-inflammatory properties and protects organs against oxidative damage (**Chandra et al., 2009**). Furthermore, **Parveen and Shadabig, (2011)**, indicated that generation of reactive oxygen species (ROS) as a result of oxidative stress of any toxic agent were depressed by antioxidant effect of *N. sativa* seeds and this was in consistent with (**Ragheb et al., 2009**) and (**Saleem et al., 2012**) who demonstrated the importance of thymoquinone as antioxidant. Recently, **El-Hakem et al., (2013)** demonstrated that combined administration of *Nigella sativa* oil and hydrocortisone ameliorate the destructive effects of hydrocortisone on the seminiferous epithelium.

Table 1. Effect of the treatment with colchicine alone or with *nigella sativa* seeds on testis antioxidant enzymes, the testis contents of GSH, MDA and NO and the level of plasma TST.

Group Parameter	Healthy group (NCG)	Colchicine treated group (PCG)	Colchicine + <i>N. sativa</i> treated group (NST)
CAT	06.53 ± 0.15	02.23 ± 0.05**	05.89 ± 0.13**
SOD	04.01 ± 0.22	02.87 ± 0.21**	03.05 ± 0.71*
GPx	35.07 ± 0.68	22.32 ± 0.80**	33.09 ± 0.65**
GSH	01.41 ± 0.01	00.23 ± 0.02**	01.11 ± 0.07**
MDA	02.98 ± 0.35	06.05 ± 0.95**	03.60 ± 0.05**
NO	67.66 ± 0.47	84.32 ± 0.84**	72.39 ± 0.18*
TST	03.06 ± 0.82	00.93 ± 0.17**	02.30 ± 0.66**

Values are expressed as mean ± S.D. for twenty animals in each group. Colchicine group (PCG) was compared with negative control (NCG) group. *N. sativa* treated group (NST) was compared with colchicine group. CAT, μmol of H_2O_2 consumed/min/mg protein; SOD, units/mg protein (one unit of the SOD activity is the amount of enzyme required to give 50% inhibition of epinephrine auto oxidation); GPx, nmol GSH oxidized/min/mg protein; GSH, μg of GSH/mg protein; MDA, nmol of MDA/mg protein; NO, nmol/mg protein; TST ng/ml.

* $p < 0.05$.

** $p < 0.001$.

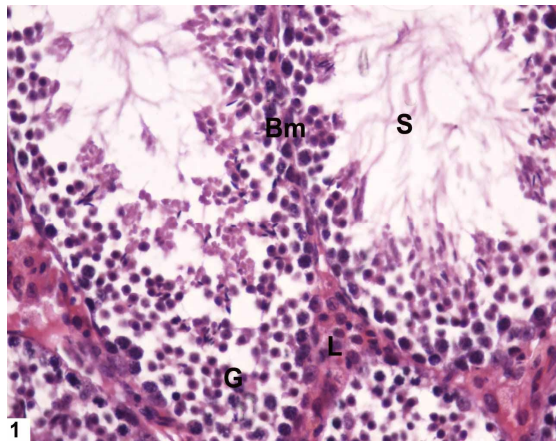
Table 2. Effect of the treatment with colchicine alone or with *N. sativa* on the testes weight, the seminal vesicles and semen analysis.

Group Parameter	Healthy group (NCG)	Colchicine treated group (PCG)	Colchicine + <i>N. sativa</i> treated group (NST)
Testes (g/100g b.wt.)	2.55 ± 0.95	1.74 ± 0.97**	2.04 ± 0.65**
Seminal vesicles (g/100g b.wt.)	1.73 ± 0.90	1.09 ± 0.65*	1.62 ± 0.96*
Normal Sperm count (million/ml)	4.34 ± 1.05	2.02 ± 1.69*	3.80 ± 1.19**
Abnormal sperm count (%)	22.33 ± 1.39	46.90 ± 2.36**	30.90 ± 6.54**
Sperm motility (%)	83.71 ± 1.84	28.67 ± 4.37**	74.56 ± 1.17**

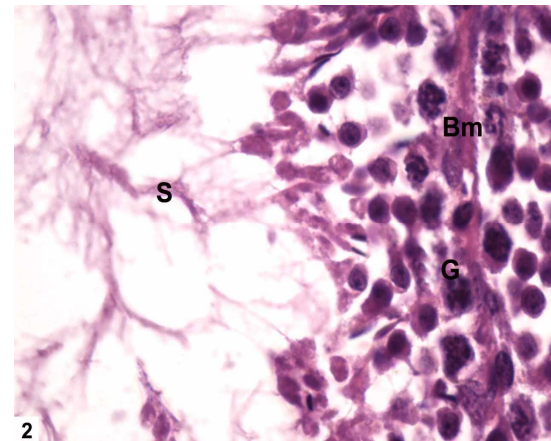
Values are expressed as mean ± S.D. for twenty animals in each group. Colchicine group (PCG) was compared with negative control (NCG) group. *N. sativa* treated group (NST) was compared with colchicine group.

* $p < 0.05$.

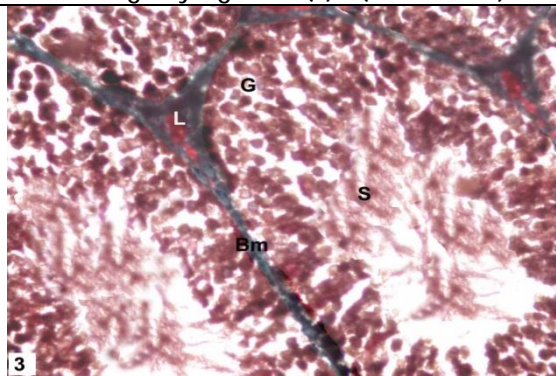
** $p < 0.001$.



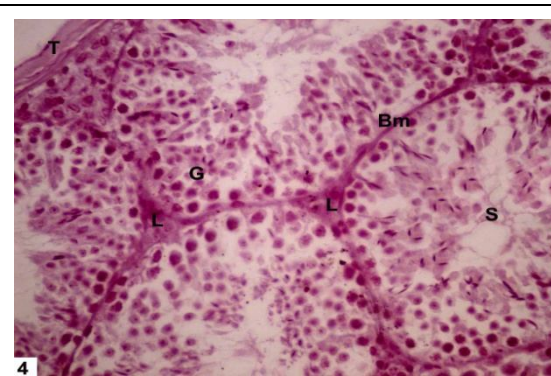
1
Fig (1) a photomicrograph of a transverse section of a control rat testis showing a group of seminiferous tubules which are surrounded by the basement membrane (bm). The germ cells (G) are arranged in layers. The sperms are seen in the lumen (s) & the interstitial tissue is present in between the tubules containing Leydig cells (L). (H&E X400)



2
Fig (2) a photomicrograph of a transverse section of a control rat testis showing a group of seminiferous tubules which are surrounded by the basement membrane (bm). The germ cells (G) are arranged in layers. The sperms are seen in the lumen (s). (H&E X1000)



3
Fig (3) A photomicrograph of a transverse section of a control rat testis showing normal thickness of basement membrane (Bm), normal arrangement of germ cells (G) and normal sperms (S)(MalloryX400)



4
Fig (4) a photomicrograph of a transverse section of a control rat testis showing a positive reaction of PAS in all its components with normal thickening of tunica albuginea (T), normal thickness of the basement membrane (bm), normal histological structure of seminiferous tubules with normal arrangement of germinal cells (G) and normal sperm (S). (Periodic acid-Schiff's X400)

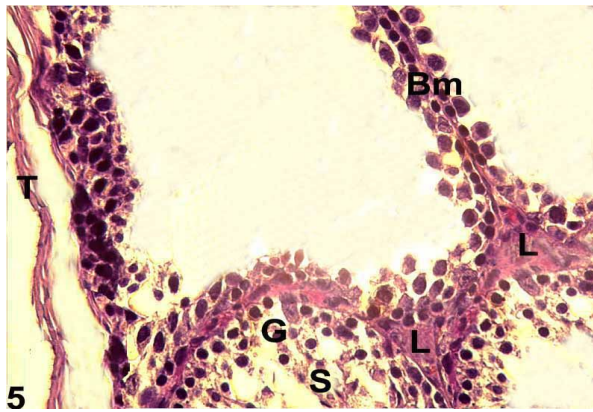


Fig (5) a photomicrograph of a transverse section of a second group rat testis showing marked disorganized and necrotic germ cells (G) lining of the seminiferous tubules degenerated sperms (S) , with degenerated interstitial cells of Leydig (L) and irregular thin basement membrane (Bm) and tunica albuginea (Ta) . (H&E X400)

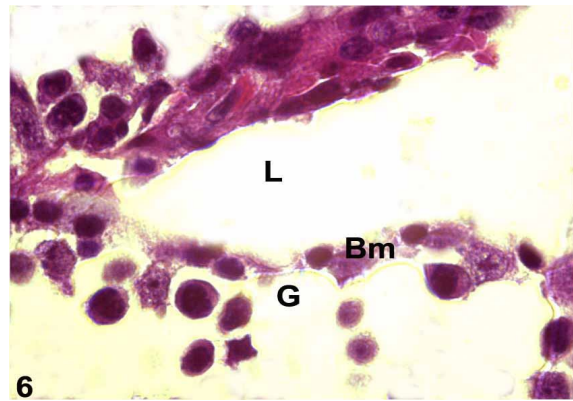


Fig (6) a photomicrograph of a transverse section of a second group rat testis showing marked disorganized and necrotic germ cells (G) lining of the seminiferous tubules with degenerated interstitial cells of Leydig (L) and irregular thin basement membrane (Bm). (H&E X1000)

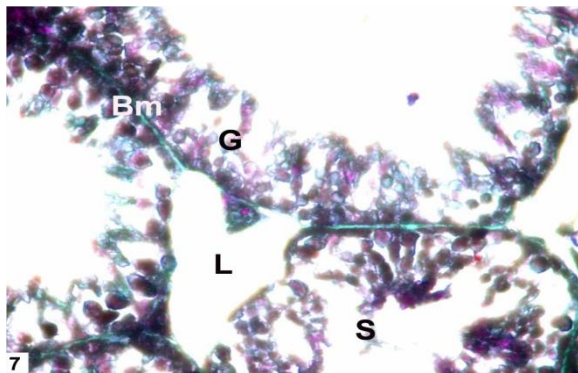


Fig (7) a photomicrograph of a transverse section of a second group rat testis showing marked disorganized and necrotic germ cells (G) lining of the seminiferous tubules with degenerated interstitial cells of Leydig (L) and damaged irregular thin basement membrane (Bm). (Mallory X400).

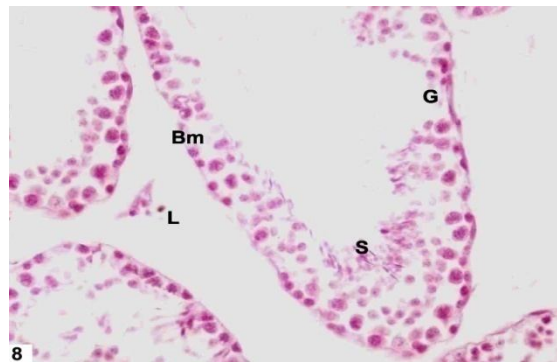
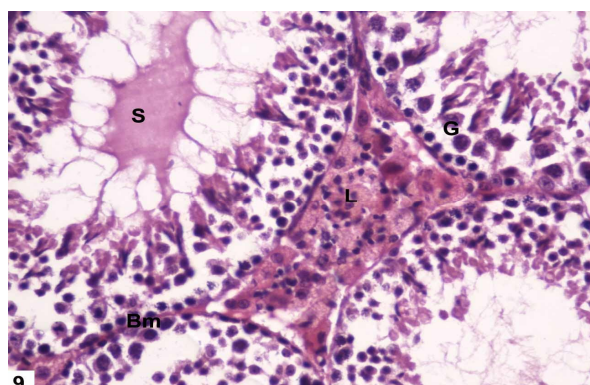
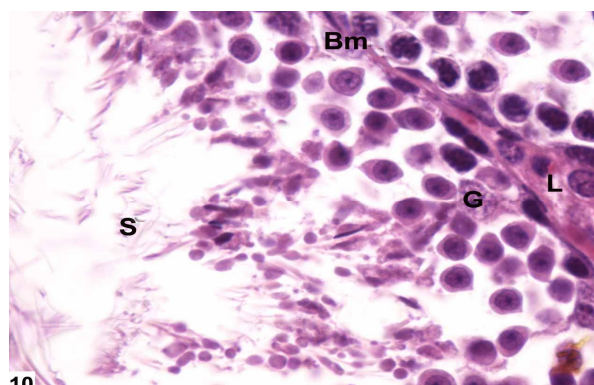


Fig (8) Photomicrograph of transverse section of testis of colchicines treated group showing low PAS positive reaction in the disorganized germ cells (G) lining of the seminiferous tubules, irregular thin basement membrane (Bm) low density of sperm(S) and degeneration of lydeing cells (L). (Periodic acid-Schiff's X400)



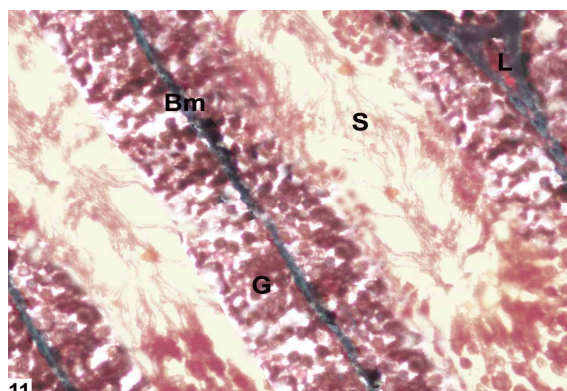
9

Fig (9) Photomicrograph of transverse section of testis of third group showing recovery of histological features of germ cells lining of the seminiferous tubules (G) , basement membrane (Bm) normal sperms in the lumen (S) as well as the interstitial cells of leydig (L). (H&E X400)



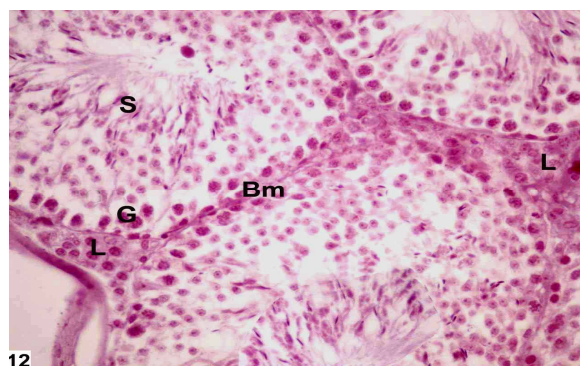
10

Fig (10) Photomicrograph of transverse section of testis of third group showing recovery of histological features of germ cells lining of the seminiferous tubules (G) , basement membrane (Bm) , normal sperms in the lumen (S) well as the interstitial cells of leydig (L). (H&E X1000)



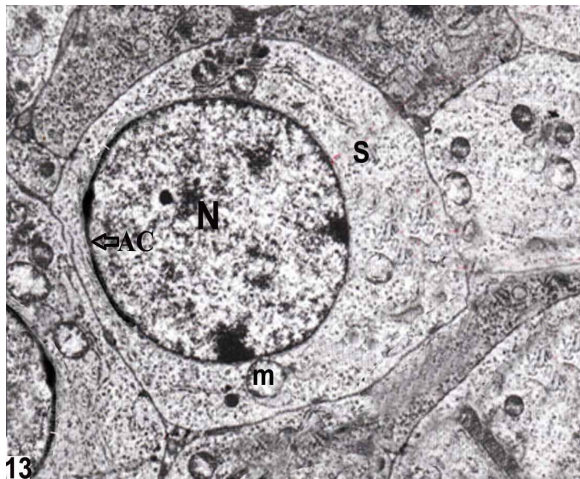
11

Fig (11) Photomicrograph of transverse section of testis of third group showing recovery of histological features of germ cells lining of the seminiferous tubules (G) , basement membrane (Bm) , normal sperms in the lumen (S) well as the interstitial cells of leydig (L). (Mallory X400)



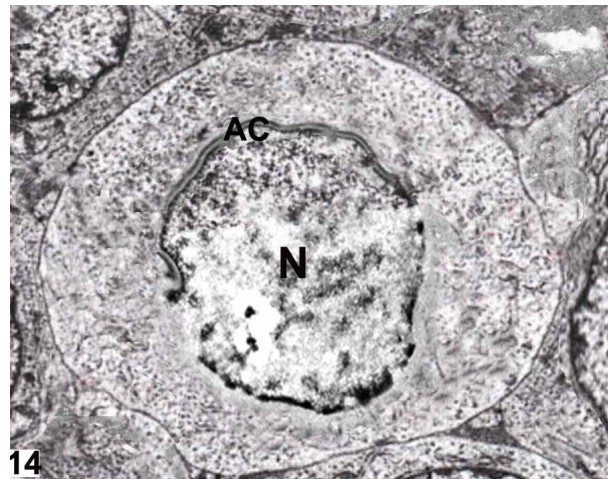
12

Fig (12) a photomicrograph of a transverse section of third group showing a positive reaction of PAS with recovery of histological features in all its components with normal thickness of the basement membrane (bm), normal histological structure of seminiferous tubules with normal arrangement of germinal cells (G) and normal sperm in the lumen(S). (Periodic acid-Schiff's X400)



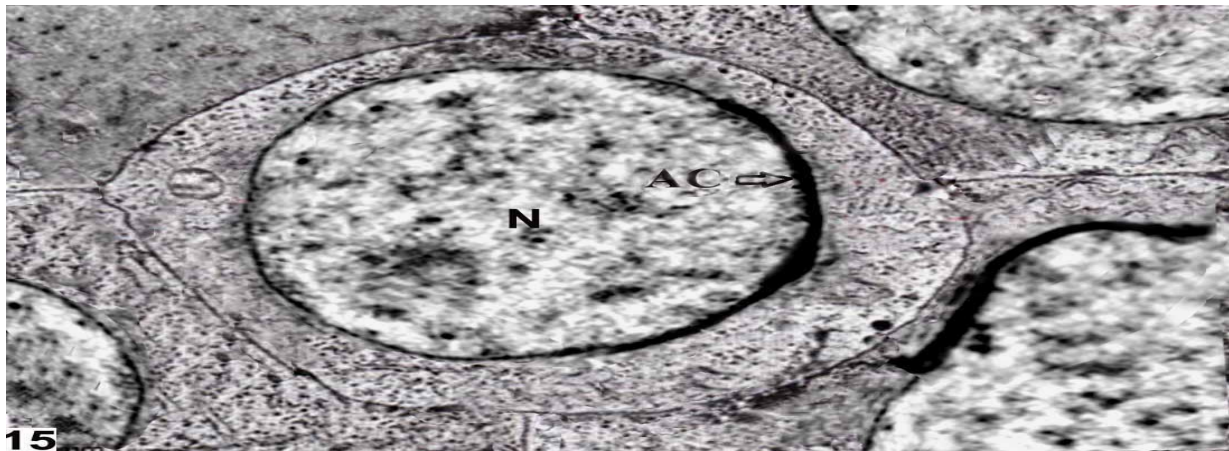
13

Fig (13) Electron micrograph of the testis of a control rat, showing normal sperm (S) and acrosomal cap of spermatid (AC) , normal nucleus (N) and mitochondria(m). X15000



14

Fig (14) Electron micrograph of the second group rat testis showing irregular acrosomal cap of spermatid (AC) and irregular nuclear membrane (N). X17000



15

Fig (15) Electron micrograph of the third group rat testis showing recovery of sperm (S) ,acrosomal cap of spermatid (AC) and recovery of nuclear membrane (N). X14000

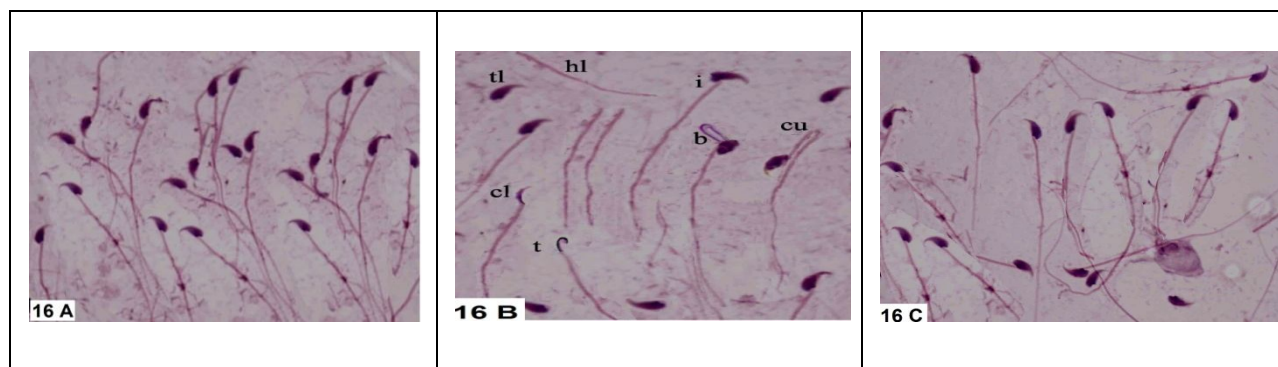


Figure 16. A photomicrograph of sperms from deferent groups(HE X 1000).

16 A, a photomicrograph of normal shaped sperms of control rats (NCG).

16 B, a photomicrograph of abnormal shaped sperms of second group rats (PCG)

t: Thin elongated head.

cl: Club-shaped head.

i: Incorrect head-neck connection.

tl: Tailless head.

hl: Headless tail.

b: Bent mid-piece.

cu: curved mid piece.

16 C, a photomicrograph of improvement of abnormal shaped sperms in third group rats (NTG).

CONCLUSION

The results of the current study revealed that continuous colchicine use leads to testicular toxicity, which can be ameliorated by the administration of *N. sativa* seeds. Thus, we can recommend the consumption of *N. sativa* as a safe, natural and potent antioxidant for patients who use colchicine drug repeatedly as a protective agent against oxidative stress induced by colchicine.

ACKNOWLEDGEMENTS

This research was funded by the deanship of scientific research and higher education, Taif University, Taif, KSA.

REFERENCES

- Abdel-Wahhab, M. A., and Aly, S. E. 2005. Antioxidant property of *Nigella sativa* (black cumin) and *Syzygium aromaticum* (clove) in rats during aflatoxicosis. *Journal of Applied Toxicology*, 25(3), 218-223.
- Aebi, H. 1984. Catalase in vitro. *Methods Enzy.* 105, 121-126.
- Ali, B. H., and Blunden, G. 2003. Pharmacological and toxicological properties of *Nigella sativa*. *Phytotherapy Research*, 17(4), 299-305.
- Allard, E. K., Johnson, K. J., & Boekelheide, K. 1993. Colchicine disrupts the cytoskeleton of rat testis seminiferous epithelium in a stage-dependent manner. *Biology of reproduction*, 48(1), 143-153.

- Bancroft, J.D and Gamble, M. 2002. Theory and practice of histological techniques. 5th, Ed., Edinburgh and London, Churchill Livingstone Pub., pp 593-620.
- Bearden, H.J., Fuquay, J.W. and Willard, S.T. 2003. Applied Animal Reproduction. 6th, Ed., Reston Publishing Co., Inc., Reston, Virginia, p: 448.
- Beauchamp, C. and Fridovich, I. 1971. Superoxide dismutase: improved assays and an assay applicable to acrylamide gels. *Analytical biochemistry*, 44(1), 276-287.
- Bradford, M. M. 1976. A rapid and sensitive method for the quantitation of microgram quantities of protein utilizing the principle of protein-dye binding. *Analytical biochemistry*, 72(1), 248-254.
- Brcic, N., Ivica, V., Relja, P., Anoeiko, D., Dinko, V and Draen, C. 2001. Accidental Plant Poisoning with Colchicum autumnale: Report of Two Cases. *Croat., Med., J.*, 42(6):673-675.
- Burits, M., and Bucar, F. 2000. Antioxidant activity of *Nigella sativa* essential oil. *Phytotherapy Research*, 14(5), 323-328.
- Chandra, S., Murthy, S.N., Mondal, D and Agrawal, K.C. 2009. Therapeutic effects of *Nigella sativa* on chronic HAART-induced hyperinsulinemia in rats. *Can., J., Physiol., Pharm.* 87,300-309.
- Creasy, D. M. 2001. Pathogenesis of male reproductive toxicity. *Toxicologic pathology*, 29(1), 64-76.
- Drury RA and Wallington EA. Carlton Histological Technique 1980. 4th ed. Oxford Press, 65-75.
- El Shenawy, N. S., Soliman, M. F., and Reyad, S. I. 2008. The effect of antioxidant properties of aqueous garlic extract and *Nigella sativa* as anti-schistosomiasis agents in mice. *Revista do Instituto de Medicina Tropical de São Paulo*, 50(1), 29-36.
- El-Hakem, A. H. A., Ewis, S. H., Ahmed, M. A. A. S. and Eid, R. A. 2013. An Ultrastructural Study on the Effect of *Nigella Sativa* and Hydrocortisone on Adult Albino Rat Testis. *Journal of American Science*, 7, 9.
- Ellman, G. L. 1959. Tissue sulfhydryl groups. *Archives of biochemistry and biophysics*, 82(1), 70-77.
- El-Tohamy, M. M. 2012. The mechanisms by which oxidative stress and free radical damage produces male infertility. *Life Science Journal*, 9(1), 674-88.
- Finkelstein, Y., Aks, S. E., Hutson, J. R., Juurlink, D. N., Nguyen, P., Dubnov-Raz, G. and Bentur, Y. 2010. Colchicine poisoning: the dark side of an ancient drug. *Clinical Toxicology*, 48(5), 407-414.
- Gali-Muhtasib, H., Roessner, A. and Schneider-Stock, R. 2006. Thymoquinone: a promising anti-cancer drug from natural sources. *The international journal of biochemistry & cell biology*, 38(8), 1249-1253.
- Green, L. C., Wagner, D. A., Glogowski, J., Skipper, P. L., Wishnok, J. S. and Tannenbaum, S. R. 1982. Analysis of nitrate, nitrite, and [15N]nitrate in biological fluids. *Analytical biochemistry*, 126(1), 131-138.

- Gulbahar, O., Adisen, H., Koca, C., Aricioglu, A. and Gulekon, A. 2007. Changes in serum carbonyl and malondialdehyde levels following colchicine and vitamin E treatment in Behcet's disease. *Methods and findings in experimental and clinical pharmacology*, 29(8), 521-524.
- Güven, A. G., Bahat, E., Akman, S., Artan, R. and Erol, M. 2002. Late diagnosis of severe colchicine intoxication. *Pediatrics*, 109(5), 971-973.
- Harris, R. D., and Gillett, M. J. 1998. Colchicine poisoning—overview and new directions. *Emergency Medicine*, 10(2), 161-167.
- Hess, R. A. and Nakai, M. 2000. Histopathology of the male reproductive system induced by the fungicide benomyl. *Histology and histopathology*, 15(1), 207-224.
- Klintschar, M., Beham-Schmidt, C., Radner, H., Henning, G. and Roll, P. 1999. Colchicine poisoning by accidental ingestion of meadow saffron (*Colchicum autumnale*): pathological and medicolegal aspects. *Forensic science international*, 106(3), 191-200.
- Kumar, A., Seghal, N., Padi, S. V., and Naidu, P. S. 2006. Differential effects of cyclooxygenase inhibitors on intracerebroventricular colchicine-induced dysfunction and oxidative stress in rats. *European journal of pharmacology*, 551(1), 58-66.
- Maxwell, M. J., Muthu, P., and Pritty, P. E. 2002. Accidental colchicine overdose. A case report and literature review. *Emergency Medicine Journal*, 19(3), 265-266.
- Milne, S. T., and Meek, P. D. 1998. Fatal colchicine overdose: report of a case and review of the literature. *The American journal of emergency medicine*, 16(6), 603-608.
- Mori, K., Kaido, M., Fujishiro, K., Inoue, N., Koide, O., Hori, H. and Tanaka, I. 1991. Dose dependent effects of inhaled ethylene oxide on spermatogenesis in rats. *British journal of industrial medicine*, 48(4), 270-274.
- Nabila, A. R. 2006. Effect of colchicine on the histology of spleen and testis of albino rats. *The Egyptian Journal of Hospital Medicine*. 23,268-276.
- Ohkawa, H., Ohishi, N., and Yagi, K. 1979. Assay for lipid peroxides in animal tissues by thiobarbituric acid reaction. *Analytical biochemistry*, 95(2), 351-358.
- Ohtani, K., Yamazaki, S., Kubota, H., Miyagawa, M., and Saegusa, J. 2004. Comparative investigation of several sperm analysis methods for evaluation of spermatotoxicity of industrial chemical: 2-bromopropane as an example. *Industrial health*, 42(2), 219-225.
- Paick, J. S. 2003. Role of Reactive Oxygen Species in Male Infertility. *Korean Journal of Andrology*, 21(1), 1-11.
- Parveen, N. and Shadabig, G.G. 2011. Ameliorative action of *nigella sativa* against iron induced chromosomal aberrations in rat bone marrow cells in vivo. *International Journal of Pharma and Bio Sciences*, 2, 470-477.
- Ragheb, A., Attia, A., Eldin, W. S., Elbarbry, F., Gazarin, S. and Shoker, A. 2009. The protective effect of thymoquinone, an anti-oxidant and anti-inflammatory agent, against renal injury: a review. *Saudi Journal of Kidney Diseases and Transplantation*, 20(5), 741-752.

- Sakuma, Y. (2009). Gonadal steroid action and brain sex differentiation in the rat. *Journal of neuroendocrinology*, 21(4), 410-414.
- Saleem, U., Ahmad, B., Rehman, K., Mahmood, S., Alam, M., and Erum, A. 2012. Nephro-protective effect of vitamin C and Nigella sativa oil on gentamicin associated nephrotoxicity in rabbits. *Pak J Pharm Sci*, 25(4), 727-730.
- Sazuka, Y., Tanizawa, H. and Takino, Y. 1989. Effect of adriamycin on the activities of superoxide dismutase, glutathione peroxidase and catalase in tissues of mice. *Cancer Science*, 80(1), 89-94.
- Sharma, R. K. and Agarwal, A. 1996. Role of reactive oxygen species in male infertility. *Urology*, 48(6), 835-850.
- Singh, G., Marimuthu, P., de Heluani, C. S. and Catalan, C. 2005. Chemical constituents and antimicrobial and antioxidant potentials of essential oil and acetone extract of *Nigella sativa* seeds. *Journal of the Science of Food and Agriculture*, 85(13), 2297-2306.
- Tekeoglu, I., Dogan, A., Ediz, L., Budancamanak, M., and Demirel, A. 2007. Effects of thymoquinone (volatile oil of black cumin) on rheumatoid arthritis in rat models. *Phytotherapy Research*, 21(9), 895-897.
- Terkeltaub, R. 2005. Pathogenesis and treatment of crystal-induced inflammation. In: Koopman WJ, Moreland LW, editors. *Arthritis and Allied Conditions*. 15th ed. Philadelphia, PA, Lippincott, Williams and Wilkins. pp. 2357-72.
- Terkeltaub, R. A., Furst, D. E., Bennett, K., Kook, K. A., Crockett, R. S. and Davis, M. W. 2010. High versus low dosing of oral colchicine for early acute gout flare: Twenty-four-hour outcome of the first multicenter, randomized, double-blind, placebo-controlled, parallel-group, dose-comparison colchicine study. *Arthritis & Rheumatism*, 62(4), 1060-1068.
- Veerendra Kumar, M. H. and Gupta, Y. K. 2002. Intracerebroventricular administration of colchicine produces cognitive impairment associated with oxidative stress in rats. *Pharmacology Biochemistry and Behavior*, 73(3), 565-571.
- Wahba, H. M. A. 2011. Protective Effect of Nigella Sativa, Linseed and Celery Oils against Testicular Toxicity Induced by Sodium Valproate in Male Rats. *Journal of American Science*, 7(5).

Corresponding author: Dr. Gaber M. G. Shehab, Head of Medical Biochemistry Department, College of medicine, Taif University, KSA.

Email: g.shehab@hotmail.com